

# TRIPLE POWER

for enhanced glycemic control

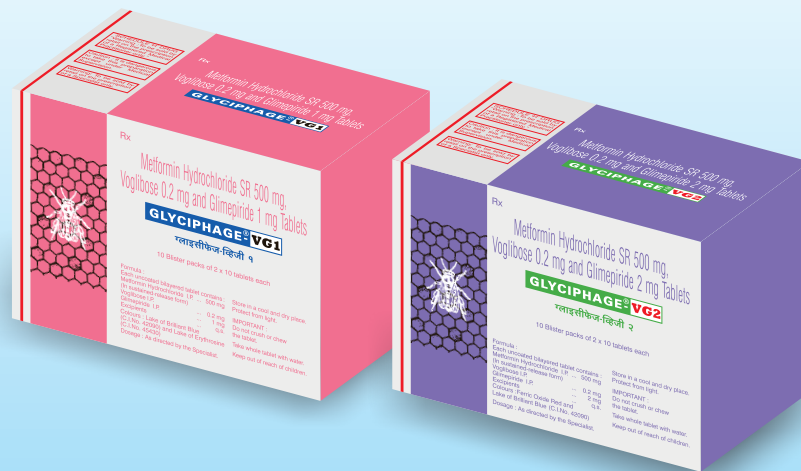

Rx

## GLYCIPHAGE<sup>®</sup>-VG

Metformin SR 500 mg + Voglibose 0.2 mg + Glimepiride 1 mg / 2 mg Tablets

### Powers HbA1c Control



  
**DIABÉTIX**

A Division of  
**FRANCO-INDIAN  
PHARMACEUTICALS PVT. LTD.**

# Cotton Bezoar Causing Intestinal Obstruction

JAGANNATH KULKARNI\*, SANJIV KUMAR GOYAL\*, GIRISH SINGLA\*

## ABSTRACT

**Background:** The unusual urge to eat cotton fibers is usually seen in people whose mental health is affected. Presentation could be in the form of trichophagy (eating hair), followed by trichobezoar or phytobezoar (eating vegetable fibers), which is a rare entity. Rapunzel syndrome is a term for trichobezoar where the parent bezoar is in the stomach and a tail of the fibers or hair extends into the jejunum. Presentation as gastric outlet obstruction due to a cotton bezoar in the stomach and intestine is rare, hence we report it here. **Case report:** A 60-year-old gentleman with no known comorbidities presented to the emergency room with history of pain abdomen, vomiting and loss of weight. Ultrasound followed by CT abdomen and pelvis revealed features of gastric outlet obstruction due to foreign body. On emergency exploratory laparotomy after initial resuscitation, he was found to have a large gastric cotton bezoar possibly extending into the proximal jejunum. The bezoar was extracted via gastrostomy and on-table enteroscopy confirmed complete evacuation of the bezoar. On postoperative Day 5, patient was discharged on soft diet. **Conclusion:** Gastrointestinal bezoars are a rare entity, and when cotton is the nature of bezoar with possible gastric outlet obstruction Rapunzel syndrome, it qualifies for inclusion into the literature.

**Keywords:** Cotton bezoar, Rapunzel syndrome, gastric outlet obstruction

Stomach bezoars if detected in time may be treated by endoscopic retrieval but if presentation is in the form of intestinal obstruction with or without perforation management is by a formal exploratory laparotomy followed up by treatment for the underlying psychiatric disorder.<sup>1,2</sup> Bezoars are rare and are often reported in patients with some psychiatric ailment.<sup>3,4</sup> They usually present with signs and symptoms due to a mass in the stomach, which may rarely extend into the jejunum as a tail (Rapunzel syndrome).<sup>1,5,6</sup> Such instances where in an elderly male patient presents to the Emergency Room (ER) with signs of gastric outlet obstruction due to cotton bezoar and successful management surgically is rare in literature.

## CASE REPORT

A 60-year-old gentleman with no known comorbidities was brought to the ER with history of pain abdomen recurrent episodes of vomiting for 4 days. On examination, he appeared dehydrated, his heart

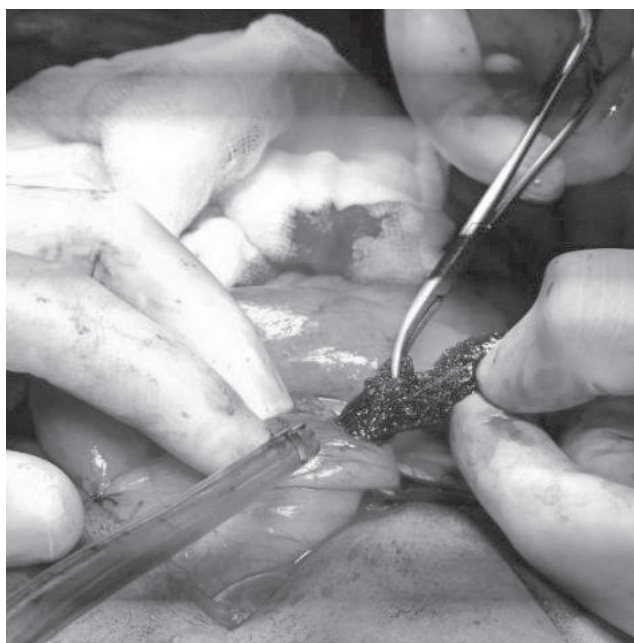
rate (HR) - 98 bpm, blood pressure (BP) - 130/80 mmHg, conscious and oriented. Per abdominal examination revealed vague palpable mass and signs of gastric outlet obstruction. Per-rectal examination had empty rectum and no growth was palpated. Other systems examination was normal.

He was resuscitated in ER with IV fluids, antispasmodics, antiemetics and was started on broad-spectrum IV antibiotics. Blood samples were sent for all the preoperative values. Baseline ECG, X-ray chest was done. Ryle's tube aspiration was started and a Foley's catheter was placed.

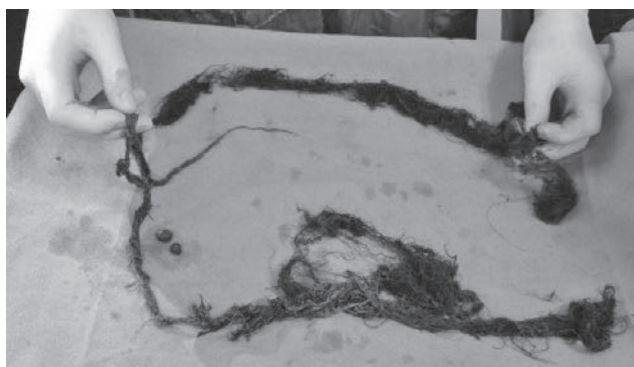
Ultrasound followed by CT abdomen showed features of gastric outlet obstruction possibly due to a foreign body. The patient underwent emergency exploratory laparotomy. Gastric palpation suggested foreign body and on gastrostomy (Fig. 1) a large and a long band/ball of cotton fibers was seen. After complete extraction of the bezoar, it was found to measure 2.4 feet in length and was made up of varying girths and colors of cotton fibers (Fig. 2).

On table enteroscopy via the gastrostomy confirmed complete extraction of the bezoar. Gastrostomy and abdomen were closed with drain. He improved over a period of 3 days after the surgery and was taking liquids on post-op Day 3. He was started on soft diet on post-op Day 5 and discharged on post-op Day 6 in stable condition.

\*Consultant Gen/Lap Surgeon  
Grecian Super Speciality Hospital, Mohali, Punjab  
Address for correspondence  
Dr Girish Singla  
Consultant Gen/Lap Surgeon  
Grecian Super Speciality Hospital, Sector 69, SAS Nagar, Mohali - 160 062, Punjab  
E-mail: drgirishsingla@gmail.com



**Figure 1.** Gastrotomy and extraction of bezoar.



**Figure 2.** Cotton bezoar measuring 2.4 feet.

## DISCUSSION AND CONCLUSION

Around 400 cases of trichobezoar and a larger number of phytobezoars have been reported in the literature but many go unreported.<sup>1,4</sup> They occur mainly in the young women who chew and swallow their hair (trichobezoar) or phytobezoar (vegetable fibers) or diospyrobezoar (persimmon fibers) or pharmacobezoar (tablets/semi-liquid masses of drugs).<sup>3,6,7</sup> With time, these are retained by mucus and become enmeshed, creating a mass in the shape of the stomach where they are usually found. They may attain large sizes owing to the chronicity of the problem and delayed reporting by the patients.

The term bezoar comes from the Arabic “badzehr” or from the Persian “panzer” both meaning counter poison or antidote.<sup>4,5</sup> Hindus used bezoars in the 12th century BC for rejuvenating the old, neutralizing snake venom and other poisons, treating vertigo, epilepsy, melancholia

and even plague. A genuine bezoar was recognized by its failure to smoke when a red-hot needle was plunged into it.<sup>3,5,6</sup>

Causes of bezoar include the presence of indigestible material in the lumen, gastric dysmotility (including previous surgery like vagotomy and partial gastrectomy, etc.) and certain other substances that encourage stickiness and concretion formation. The clinical presentation may be a palpable, firm, nontender epigastric mass, which is either discovered, on routine physical examination in an asymptomatic patient. Bezoars have been reported between the ages of 1 and 56 years, most presenting between the ages of 15-20 years and 90% are in females. Approximately 10% show psychiatric abnormalities or mental retardation.<sup>1</sup>

Rarely, the bezoars may extend into the small intestine as a tail (Rapunzel syndrome after “Rapunzel” the fair, long haired maiden in the Grimm brother’s fairy tale who lowered her tresses to allow Prince charming to climb up to her prison tower to rescue her) or may get broken lodging in the intestine to cause intestinal obstruction, ulceration, bleeding and perforation. Small intestinal bezoars have also been reported after truncal vagotomy and with compression of the duodenum by the superior mesenteric artery.<sup>8</sup>

Bezoars mostly originate in the stomach and are probably related to high fat diet causing non-specific symptoms like epigastric pain, dyspepsia and postprandial fullness; the stomach is not able to push the hair/cotton or other substance out of the lumen because the friction surface is insufficient for propulsion by peristalsis.<sup>3,5,6</sup> They may also present with gastrointestinal bleeding (6%) and intestinal obstruction or perforation (10%).<sup>3,5,6</sup> Diagnosis at an early stage is important since conservative treatment (fragmentation and endoscopic extraction, enzymatic destruction) is possible for gastric bezoars.

If available, endoscopic examination of the stomach is the preferred method of exploring the stomach for the concomitant bezoar while managing a case of intestinal bezoar. Exploration may reveal concomitant gastric bezoar, which may be retrieved endoscopically or by gastrotomy.<sup>7</sup> Escamilla et al reported 23 cases of concomitant gastric bezoars (extracted by gastrotomies) out of 87 cases of intestinal bezoars.<sup>7</sup> If detected in the intestine, they may be milked down to the enterotomy site for retrieval through one opening or they may require multiple enterotomies.

Treatment is removal of the mass by a single enterotomy or resection of the bowel if not viable.<sup>2,7</sup> Duncan et al

## SURGERY

recommended bezoar extraction by multiple enterotomies in the Rapunzel syndrome.<sup>9</sup> DeBakey and Ochsner reported an operative mortality of 10.4%.<sup>10</sup> It is mandatory to do a thorough exploration of the rest of the small intestine and the stomach to look for retained bezoars.<sup>11</sup>

### REFERENCES

1. Senapati MK, Subramanian S. Rapunzel syndrome. *Trop Doct.* 1997;27(1):53-4.
2. Santiago Sánchez CA, Garau Díaz P, Lugo Vicente HL. Trichobezoar in a 11-year old girl: a case report. *Bol Asoc Med P R.* 1996;88(1-3):8-11.
3. Andrus CH, Ponsky JL. Bezoars: classification, pathophysiology, and treatment. *Am J Gastroenterol.* 1988;83(5):476-8.
4. Sharma RD, Kotwal S, Chintamani, Bhatnagar D. Trichobezoar obstructing the terminal ileum. *Trop Doct.* 2002;32(2):99-100.
5. Allred-Crouch AL, Young EA. Bezoars - when the 'knot in the stomach' is real. *Postgrad Med.* 1985;78(5):261-5.
6. Goldstein SS, Lewis JH, Rothstein R. Intestinal obstruction due to bezoars. *Am J Gastroenterol.* 1984;79(4):313-8.
7. Escamilla C, Robles-Campos R, Parrilla-Paricio P, Lujan-Mompean J, Liron-Ruiz R, Torralba-Martinez JA. Intestinal obstruction and bezoars. *J Am Coll Surg.* 1994;179(3):285-8.
8. Doski JJ, Priebe CJ Jr, Smith T, Chumas JC. Duodenal trichobezoar caused by compression of the superior mesenteric artery. *J Pediatr Surg.* 1995;30(11):1598-9.
9. Duncan ND, Aitken R, Venugopal S, West W, Carpenter R. The Rapunzel syndrome. Report of a case and review of the literature. *West Indian Med J.* 1994;43(2):63-5.
10. DeBakey M, Ochsner W. Bezoars and concretions: A comprehensive review of the literature with an analysis of 303 collected cases and a presentation of 8 additional cases. *Surgery.* 1939;5:132-60.
11. Chintamani, Durkhure R, Singh JP, Singhal V. Cotton Bezoar - a rare cause of intestinal obstruction: case report. *BMC Surg.* 2003;3:5.

◆◆◆◆

