

## CASE REPORT

# Rare Adverse Effect of a Commonly Used Drug in Chronic Kidney Disease

ARUN JOSHI\*, ARUN DUA\*, PAVITRA MANU DOGRA†, VIVEK SOOD‡

### ABSTRACT

Chronic kidney disease (CKD) and hypertension can lead to each other. Majority of the patients with CKD have hypertension. Sympathetic overactivity has been suggested as one of the important etiologies of hypertension in CKD patients. Clonidine is used as a central sympatholytic to control hypertension in CKD patients. Drug-induced sialadenitis has been reported with multiple drugs including antihypertensives. We report a case of clonidine-induced sialadenitis, which has been rarely seen despite the widespread use of this drug among CKD patients requiring multiple antihypertensive drugs.

**Keywords:** Hypertension, clonidine, sialadenitis, parotitis

Chronic kidney disease (CKD) currently affects more than 10% of the world population<sup>1</sup>. Majority of the CKD patients have hypertension, which is considered one of the leading causes of increased cardiovascular disease (CVD) among CKD population<sup>2</sup>. Usually CKD patients with hypertension require multiple antihypertensive drugs for optimization of blood pressure (BP)<sup>3</sup>. Clonidine is one of those extensively used antihypertensives with central sympatholytic effect<sup>4</sup>. Parotitis has been reported with other antihypertensives like nicardipine, nifedipine, captopril, and ramipril, but despite animal studies showing effect on salivation its very rare to find parotitis with clonidine<sup>5</sup>. We are reporting here in a rare case of clonidine-induced bilateral parotitis. To the best of our knowledge, this is the first reported case of bilateral parotitis caused by clonidine.

### CASE REPORT

A 58-year-old gentleman presented to the Emergency Room of our hospital with generalized weakness and sweating for about an hour. He denied any history

of chest pain, retrosternal heaviness, breathlessness, headache, vomiting, weakness of any limb or similar such episode in the past. He denied any history of fever and he did not have any urinary complaints. He had a history of diabetes mellitus and hypertension since 1 year and was taking tablet glimepiride 2 mg and tablet amlodipine 5 mg post-breakfast daily. He denied any other chronic illness, drug allergy or any atopic history. He was a nonalcoholic and nonsmoker.

On examination, his pulse was 84/min and his BP was 160/100 mmHg with SpO<sub>2</sub> of 97% on room air. He had pallor and his systemic examination was within normal limits. His blood glucose was 55 mg/dL. His electrocardiogram (ECG) showed normal sinus rhythm and arterial blood gas showed mild metabolic acidosis with calculated bicarbonate of 21 mEq/L. He was promptly managed with intravenous dextrose and tablet amlodipine was increased to 10 mg/day with which he improved symptomatically with normal blood sugar and BP levels.

He underwent further evaluation, which showed hemoglobin 10.0 g/dL, serum creatinine 2.4 mg/dL, serum potassium 5.5 mEq/L, serum calcium 8.2 mg/dL, and inorganic phosphorus 6.0 mg/dL. Urine, dipstick showed albumin 2+ and ultrasonography showed normal sized kidneys. Funduscopy showed mild nonproliferative diabetic retinopathy in both eyes. Once he was admitted he was not on any oral hypoglycemic agent and on monitoring, his blood sugar levels were within normal limits.

His BP was controlled with tablet amlodipine 10 mg in the morning.

\*Former Senior Resident

†Professor

‡Associate Professor

Dept. of Nephrology, Army Hospital Research and Referral, New Delhi, India  
Address for correspondence

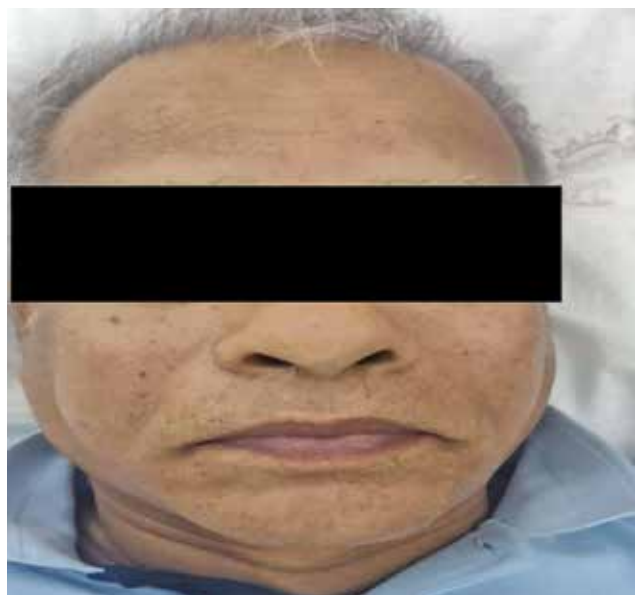Dr Arun Joshi

Assistant Professor of Medicine & Consultant Nephrology, Graphic Era Institute of Medical Sciences, Dehradun, Uttarakhand - 248007, India

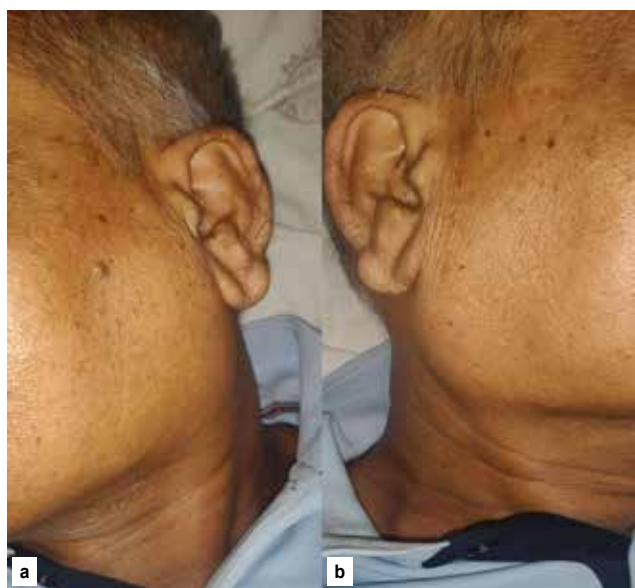
E-mail: arunvmc@gmail.com

## CASE REPORT

On the second day of his admission, he complained of headache without any other associated symptoms. His BP was 160/100 mmHg in the evening with blood glucose of 110 mg/dL and hence the resident on call gave him tablet clonidine 100 µg. He developed bilateral parotid swelling in about 20 to 30 minutes after taking clonidine. There were no symptoms suggestive of angioedema such as wheezing, swelling of other mucosal or submucosal tissues, rash or pruritus. He denied history of dry mouth or excessive salivation, pain in the swelling, difficulty in swallowing. His vitals were normal and systemic examination was within normal



**Figure 1.** Frontal view showing bilateral parotid gland enlargement.



**Figure 2.** Parotid gland swelling: Left (a) and Right (b).

limits. He had bilateral painless parotid enlargement (Figs. 1 and 2). He was given oral antihistaminics and the swelling decreased over the next few hours and over the next 2 to 3 days it totally disappeared. Even on follow-up patient was asymptomatic and on examination, he did not have parotid swelling. He was continued on tablet amlodipine 10 mg OD with blood glucose and BP monitoring.

## DISCUSSION

Hypertension affects ~30% of the general adult population and up to 90% of those with CKD<sup>6</sup>. It is both a cause and effect of CKD and both are independent risk factors for CVD and lowering BP can slow glomerular filtration rate (GFR) decline as well as reduce cardiovascular events<sup>7</sup>.

There are different mechanisms contributing to the development of hypertension in CKD and hence influencing its management like increase in sympathetic tone brought about by afferent signals generated by functionally declining kidneys, renin-angiotensin-aldosterone system activation, which promotes salt and water retention, endothelial dysfunction in advanced CKD (eGFR <30 mL/min/1.73 m<sup>2</sup>) and increased arterial stiffness throughout the spectrum of CKD<sup>8</sup>. There is a limited evidence on the use of specific antihypertensive agents to treat high BP in CKD and majority will need combinations of two or more antihypertensive drugs for achieving the BP goals<sup>3</sup>. Any antihypertensive treatment algorithm in CKD, beyond monotherapy, is based on expert opinion, pathophysiologic or pharmacodynamic considerations, patient tolerance, patient preferences, comorbid illnesses, etc. The treatment algorithm for intensive systolic BP arm in SPRINT (Systolic Blood Pressure Intervention Trial) protocol suggested to begin with 2- or 3-drug therapy using a combination of a thiazide-type diuretic, and/or an angiotensin-converting enzyme (ACE) inhibitor or angiotensin receptor blocker but not both and/or a calcium channel blocker (CCB)<sup>9</sup>.

Clonidine or 2-(2,6-dichlorophenylamino)-2-imidazoline hydrochloride is a 40-year-old imidazoline derivative that acts centrally on pre-synaptic alpha-2 receptors located in the rostral ventrolateral medulla. It reduces the sympathetic outflow from the central nervous system and decreases plasma norepinephrine levels leading to decreased cardiac output and reduction in BP<sup>10</sup>. It is commonly used in CKD patients because of the hypertension pathology in CKD as explained earlier and requirement of multiple antihypertensive drugs in CKD patients for optimal BP control.

Parotitis is described as the swelling and inflammation of one or both parotid glands. Unilateral parotitis is usually associated with ductal obstruction, whereas bilateral parotitis more likely reflects systemic causes with common etiologies like viral and bacterial infections, ductal obstruction and systemic noninfectious causes such as Sjogren syndrome<sup>5</sup>. Drug-induced parotitis, while rare, has been reported with numerous drugs like l-asparaginase, clozapine, phenylbutazone, methylidopa, interferon-alfa, oxyphenbutazone, trimethoprim/sulfamethoxazole, chlormethiazole, methimazole, naproxen, nitrofurantoin, sulfadiazine, cytarabine, cimetidine, ranitidine, and thioridazine<sup>5</sup>. Among antihypertensives, nifedipine, ramipril, and captopril have been reported to cause parotitis<sup>11</sup>. No reports were found that implicated other CCBs in the development of parotitis, so it should not be considered a class effect.

In our case with the temporality of events and the scarcity of drugs patient was being treated with, clonidine was highly likely to have caused this rare adverse event and the Naranjo Adverse Drug Reaction Probability Scale<sup>12</sup> showed probable adverse drug reaction for the clonidine-induced parotitis in our case. The other important learning was to rule out the dreaded anaphylactic reaction associated with ACE inhibitor, which patient might be taking for hypertension and can lead to catastrophic event if not dealt promptly, which fortunately our patient did not have.

## CONCLUSION

Hypertension affects majority of patients suffering with CKD. Blood pressure control reduces cardiovascular morbidity, mortality, and slows the decline of GFR. Patients with CKD require multiple drugs for BP control and clonidine is one of the commonly used drugs in this cohort of patients. Acute parotitis has been associated with few antihypertensive drugs and can cause panic for the patient and the treating physician. Our patient had this rare side effect and that too with clonidine, which has very rarely been seen and can be managed easily with prompt diagnosis and appropriate intervention.



## REFERENCES

1. Kovesdy CP. Epidemiology of chronic kidney disease: an update 2022. *Kidney Int Suppl* (2011). 2022;12(1):7-11.
2. Collins AJ, Foley RN, Chavers B, Gilbertson D, Herzog C, Ishani A, et al. US Renal Data System 2013 Annual Data Report. *Am J Kidney Dis*. 2014;63(1 Suppl):A7.
3. Kidney Disease: Improving Global Outcomes (KDIGO) Blood Pressure Work Group. KDIGO 2021 clinical practice guideline for the management of blood pressure in chronic kidney disease. *Kidney Int*. 2021;99(3S):S1-S87.
4. Kuzmin OB, Buchneva NN, Zhezha VV, Serdyuk SV. Uncontrolled arterial hypertension: kidney, neurohormonal imbalance, and approaches to antihypertensive drug therapy. *Kardiologiia*. 2019;59(12):64-71.
5. Brooks KG, Thompson DF. A review and assessment of drug-induced parotitis. *Ann Pharmacother*. 2012;46(12):1688-99.
6. Muntner P, Anderson A, Charleston J, Chen Z, Ford V, Makos G, et al; Chronic Renal Insufficiency Cohort (CRIC) Study Investigators. Hypertension awareness, treatment, and control in adults with CKD: results from the Chronic Renal Insufficiency Cohort (CRIC) Study. *Am J Kidney Dis*. 2010;55(3):441-51.
7. Gansevoort RT, Correa-Rotter R, Hemmelgarn BR, Jafar TH, Heerspink HJ, Mann JF, et al. Chronic kidney disease and cardiovascular risk: epidemiology, mechanisms, and prevention. *Lancet*. 2013;382(9889):339-52.
8. Pugh D, Gallacher PJ, Dhaun N. Management of hypertension in chronic kidney disease. *Drugs*. 2019;79(4):365-79.
9. SPRINT Research Group; Wright JT Jr, Williamson JD, Whelton PK, Snyder JK, Sink KM, Rocco MV, et al. A randomized trial of intensive versus standard blood-pressure control. *N Engl J Med*. 2015;373(22):2103-16.
10. Yasaei R, Saadabadi A. Clonidine. [Updated 2023 Jul 17]. In: StatPearls [Internet]. Treasure Island (FL): StatPearls Publishing; 2024 Jan-. Available from: <https://www.ncbi.nlm.nih.gov/books/NBK459124/>
11. Chauhan V, Negi RC, Sharma A, Gupta S, Mokta J, Verma B, et al. Enalaprilat induced acute parotitis. *J Assoc Physicians India*. 2008;56:128-9.
12. Naranjo CA, Busto U, Sellers EM, Sandor P, Ruiz I, Roberts EA, et al. A method for estimating the probability of adverse drug reactions. *Clin Pharmacol Ther*. 1981;30(2):239-45.