

# XY Female with Complete Androgen Insensitivity Syndrome with Bilateral Inguinal Hernia

BHAVANA S

## ABSTRACT

Complete androgen insensitivity syndrome (CAIS) is an X-linked recessive rare disorder in which the individual is phenotypically female and genotypically male; a male pseudohermaphrodite. CAIS is suspected when the individual is evaluated for primary amenorrhea, infertility or when unilateral/bilateral inguinal hernia is diagnosed in girls. We report the case of a 30-year-old, married lady presented to Gynecology OPD with complaints of swelling in the groin, on both the sides since 4 months. She was investigated and all her blood tests were of male range and in accordance with CAIS. Bilateral gonadectomy with herniorrhaphy was done and the patient was discharged on estrogen replacement therapy.

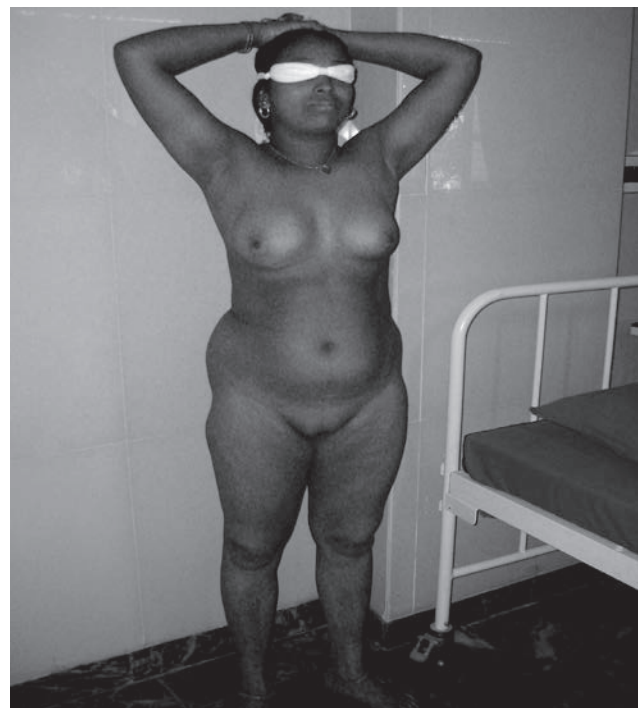**Keywords:** Complete androgen insensitivity syndrome, inguinal hernia, bilateral gonadectomy, herniorrhaphy, estrogen replacement therapy

The complete androgen insensitivity syndrome (CAIS), previously called testicular feminization syndrome is an X-linked recessive rare disorder. The individual is phenotypically female and genotypically male; a male pseudohermaphrodite. The individuals are reared as girls and the condition is suspected when the individual is evaluated for primary amenorrhea, infertility or when unilateral/bilateral inguinal hernia is diagnosed in girls.

## CASE REPORT

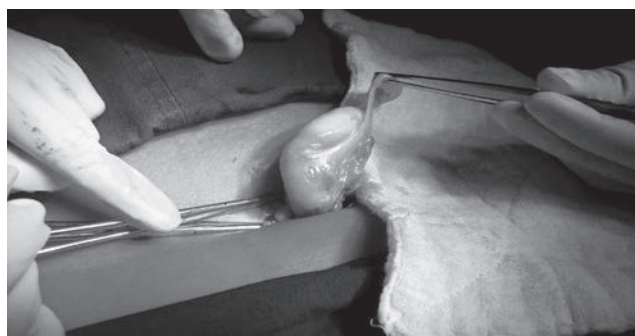
A 30-year-old, married lady presented to Gynecology OPD with complaints of swelling in the groin, on both the sides since 4 months. The swelling increased on coughing, straining; reduced on lying down. There was no history suggestive of obstruction/irreducibility. She had not attained menarche. She is married to a widower since 8 years. The husband has 2 children from first wife. They have no problems during sexual intercourse. She has 3 siblings; all are married and have children.

On examination, she was a tall, well-built and well-nourished female. Height - 167 cm, weight - 74 kg, arm span - 165 cm, thyroid - normal, secondary sexual characters-axillary hair and pubic hair absent, breasts-Tanner 3 (well-developed with pale areolae, immature nipple (Fig. 1). The abdomen was soft. The external genitalia was female. On per speculum examination, 4 cm



**Figure 1.** External appearance: Female, absent axillary and pubic hair, well developed breasts present.

Assistant Professor  
 Dept. of Obstetrics and Gynecology  
 Sree Mookambika Institute of Medical Sciences, Padanilam, Kulasekharam,  
 Kanyakumari, Tamil Nadu  
**Address for correspondence**  
 Dr Bhavana S  
 No 27, Karthik Nilaya, C-Layout, 2nd Cross, Hanumanthanagar, Bannimantap,  
 Mysore - 570 015, Karnataka  
 E-mail: bhavana\_yajat@yahoo.com



**Figure 2.** Intraoperative appearance of the contents of the herniating sac on the left side: Gonad, tubular structure, fibromuscular band.

long blind vaginal pouch was seen. The inguinal region on the right and left side showed, a pyriform nontender swelling of  $2.5 \times 2.5 \text{ cm}^2$  and  $2 \times 2 \text{ cm}^2$ , respectively, descending till upper part of labia majora. The swellings were felt above and medial to pubic tubercle and cough impulse was present. Thus clinically bilateral inguinal hernia was diagnosed.

Sonography showed absent uterus and ovaries, oval hypoechoic structures on both sides of inguinal region suggestive of bilateral inguinal hernia. The abdominal organs were normal. Laparoscopy confirmed absence of uterus and ovaries. The chromosomal analysis, Trypsin and Giemsa produce G-banded chromosomes (GTG) banded karyotyping showed 46 XY pattern. The blood investigations: Serum testosterone - 3.04 ng/mL (male range 1.8-9.0 ng/mL, female 0.2-1.2 ng/mL); luteinizing hormone or LH - 21.04 mIU/mL (male age 20-70 years: 1.5-9.3 mIU/mL, >70 years 1.3-34.6 mIU/mL); follicle-stimulating hormone (FSH) - 2.53 mIU/mL (male 1.4-18.1 mIU/mL); serum estradiol 55.17 - pg/mL (male 11.6-42.0 pg/mL). All the blood tests were of male range and in accordance with CAIS.

After counseling, the patient was posted for surgery: Bilateral gonadectomy with herniorrhaphy. Intraoperatively the contents of the sac were gonads, tubular remnant and fibromuscular band on both sides (Fig. 2). The histopathology report confirmed testicular tissue with smooth muscle fragments, on both the sides. The postoperative period was uneventful. The patient was discharged on the 10th day. Estrogen replacement therapy with tablet premarin 0.625 mg daily was advised.

## DISCUSSION

Androgen insensitivity syndrome is a rare disorder with incidence of 1 in 20,000-99,000 genetic males and the prevalence is 0.8-2.4% in phenotypic females with inguinal hernia.<sup>1</sup> The basic etiology is the loss of

function- mutation in the androgen receptor gene. The affected individuals have 46 XY karyotype, normal testes, normal production of testosterone, normal conversion to dihydrotestosterone, normal amount of antimullerian hormone. Thus the uterus, cervix, fallopian tubes and proximal vagina do not develop. In the fetal period, insensitivity to testosterone prevents masculinization of external genitalia. The lower one-third of vagina develops, as it originates from urogenital sinus and presents as a blind vaginal pouch. There is absence of axillary and pubic hair, lack of acne, absence of voice changes at puberty. The breasts are well-developed due to conversion of testosterone to estradiol. The testes may be located anywhere along the path of embryonic testicular descent in the abdomen, inguinal canal or labia. About 80-90% of individuals with CAIS develop inguinal hernia.<sup>1</sup>

The testes in CAIS individuals cause pubertal feminization. Some studies have shown carcinomatous changes in the testes of the children of CAIS in the age group of 13-14 years and believe that testicular biopsy is warranted as soon as the syndrome is diagnosed. The recent studies reveal tumor incidence (dysgerminoma, gonadoblastoma) of 0.8% in CAIS and 5.5% in AIS overall, and the risk increases markedly after puberty and reaches 33% at the age of 50 years.<sup>1,2</sup> Thus, gonadectomy is advised after puberty. Once the testes have been removed, estrogen needs to be supplemented to maintain external female form, to prevent osteoporosis and cardiovascular changes due to the deprivation of estrogen.<sup>1</sup>

The studies have shown that individuals reported psychological trauma at diagnosis, which was compounded by interaction with the medical care system.<sup>1</sup> During counseling it was found that, the patient was reared as a female and leading a happy married life. Thus informing the patient about the karyotype would be inadvisable and would have devastating psychological problems to the patient and family. Thus, they were informed that mullerian aplasia occurred and gonads were abnormally located, with chances of malignancy and should be removed. The interaction and counseling of the affected individual and family needs sensitivity and care.

## REFERENCES

1. Oakes MB, Eyvazzadeh AD, Quint E, Smith YR. Complete androgen insensitivity syndrome - a review. *J Pediatr Adolesc Gynecol.* 2008;21(6):305-10.
2. Cools M, Drop SL, Wolffenbuttel KP, Oosterhuis JW, Looijenga LH. Germ cell tumors in the intersex gonad: old paths, new directions, moving frontiers. *Endocr Rev.* 2006;27(5):468-84.



#### MRI

- Latest MRI by Siemens
- Ultra Short Magnet = No Claustrophobia
- 1st MRI in India on VC 15 Platform



#### CT Scan

- 16- Multislice Spiral CT
- Safest Scanner
- Least Radiation Dose



#### Health Packages

- Executive Health Check Up
- Risk Categories
- Age Based Health Packages

## Fully Automated Digital Pathology Laboratory - NABL Accredited



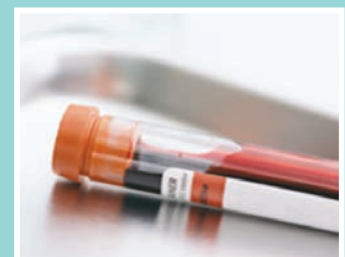Immunology



Biochemistry



Haematology



Special Tests

## Contact Us

S-63 Greater Kailash Part 1  
Opposite M Block Market, New Delhi 110048  
Tel.: 011- 41234567