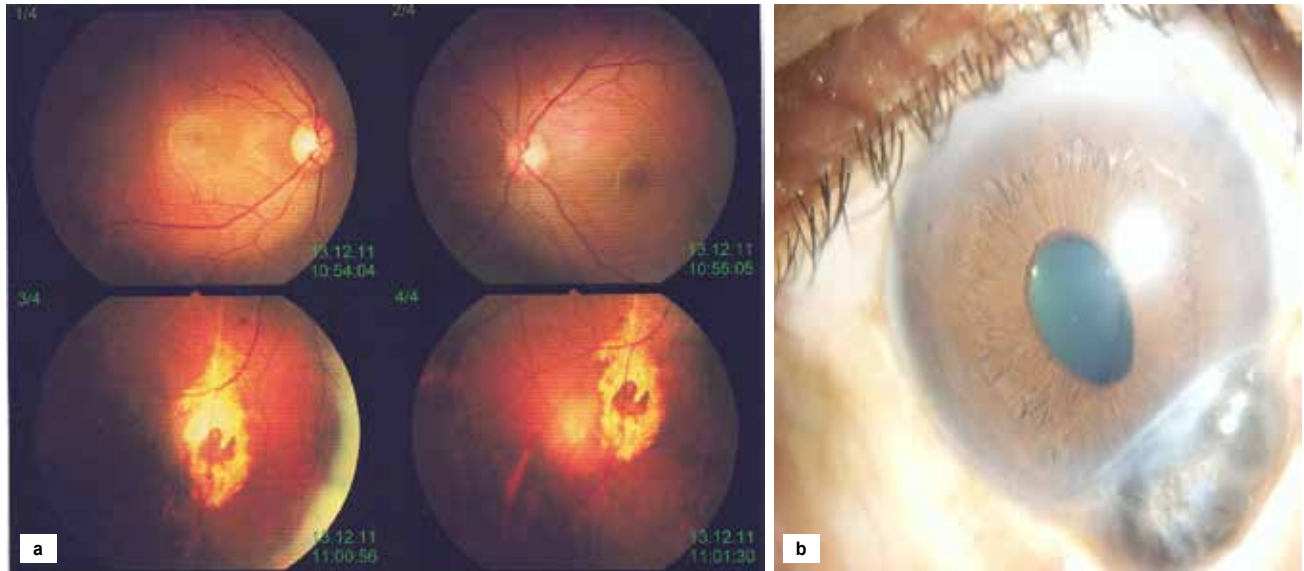


PICTURE QUIZ

What is the Diagnosis?

Which among the following is a case of rubella retinopathy?



Answer to the Picture Quiz from the Indian Journal of Clinical Practice, Vol. 35, No. 7, December 2024

Answer: (a) Apple peel jejunal atresia

See Answer in the Next Month's Issue!