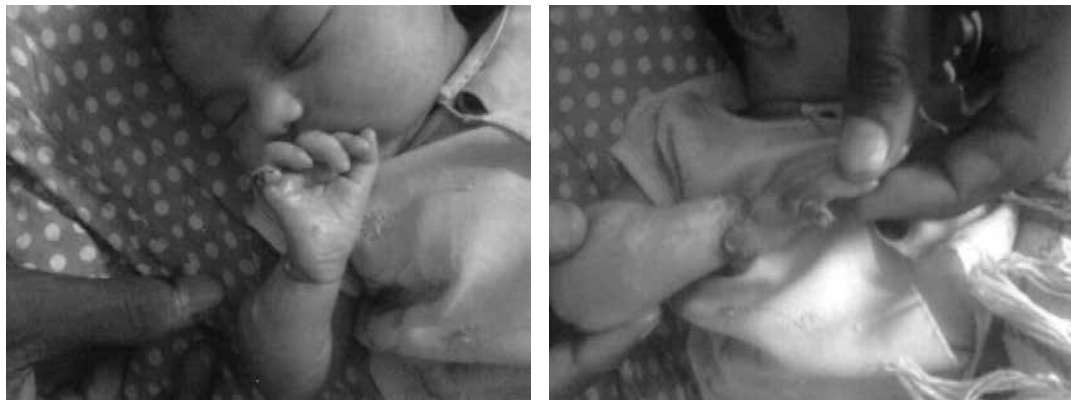

PICTURE QUIZ

What is the Diagnosis?

This baby boy is delivered by cesarean section and had constriction band at terminal phalanx of right little finger with constriction band at right wrist. What is the likely diagnosis?

- a) Amniotic band syndrome
- b) Syndactyly
- c) Radial ray deficiency
- d) Polydactyly

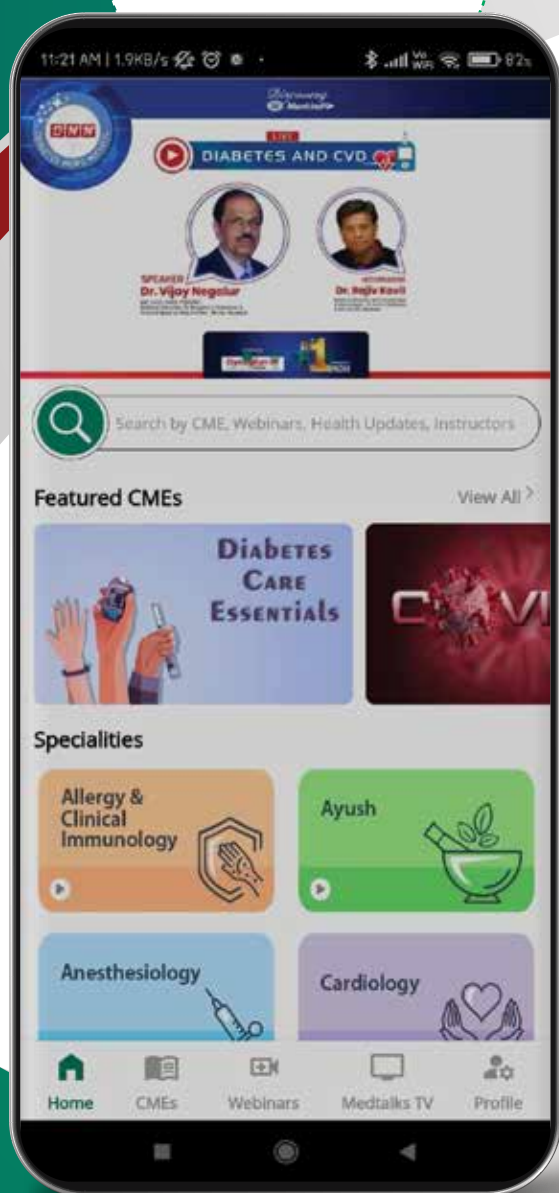


Answer to the Picture Quiz from the Indian Journal of Clinical Practice, Vol. 35, No. 5, October 2024

Answer: (D) Both (b) and (c)

See Answer in the Next Month's Issue!

5,00,000+
REGISTERED
DOCTORS



CMEs

Develop and increase Knowledge and Professional Skills



MEDTALKS TV

Discussions focused on Healthcare Awareness & Treatment



CONFERENCES

Get updates about Medical Conferences in your area.



MEDBYTES

Medical and Healthcare Education



WEBINAR

Live Webinars by renowned Doctors

DOWNLOAD



A Video Education Platform

www.medtalks.in