

# Dreaded Complication of Free Flap Failure Managed Intelligently

ASHOK SHARMA\*, SANJIV K GOYAL\*, SANDEEP SINGH MAAVI†, VIJAY JAGAD‡, AMITABH KUMAR UPADHYAY#

## ABSTRACT

Salvage surgery in head and neck carcinoma is often followed by dreaded postoperative complication. Reconstruction with free flap is usually the ideal treatment option. Here, we present the case of a 46-year-old man with necrosis of free flap in post-radiotherapy carcinoma buccal mucosa. The flap was thus taken down and was replaced by a large pectoralis major myocutaneous flap to cover the intra-oral defect and part of the facial defect. The area in front of ear was left bare, to be reconstructed after stabilization of the patient. Later, the patient was taken up for surgery and posterior auricular flap was used to cover the defect anterior to the ear. Astute knowledge of local flap with preserved blood supply is thus needed in post-radiotherapy cases with failure of free flap.

**Keywords:** Head and neck carcinoma, free flap, salvage surgery

Salvage surgery in head and neck carcinoma is often met with dreaded postoperative complication. Reconstruction with free flap becomes the ideal intervention as it gets new blood supply to the area and hence theoretically improves the chances of viability of flap. In case of necrosis of free flap, very little options are left for the cover of the defect. Here, we are presenting the case of necrosis of free flap in post radiotherapy carcinoma buccal mucosa. After multiple surgeries, patient received adequate cover of the defect with local flaps but with poor functionality.

## CASE REPORT

A 46-year-old man presented to us with history of ulcer in left buccal mucosa and severe trismus for past 3 months. In past, patient had undergone surgery and radiation for carcinoma left buccal mucosa 1½ year back.

On examination, patient had severe trismus Grade IV and the lesion was seen starting from left anterior commissure; due to severe trismus, posterior extent

of the lesion was not assessable. Magnetic resonance imaging (MRI) scan of the face and neck revealed irregular thickened lesion involving whole of left buccal mucosa extending from upper alveolus to the lower gingivobuccal sulcus. Biopsy from the buccal mucosal lesion revealed squamous cell carcinoma. In accordance with the extent of lesion and the post radiotherapy status of the neck skin, we planned for wide excision and cover with free flap.

Patient underwent wide excision with left hemimandibulectomy, left upper alveolectomy and cover with anterolateral free flap. Post-op on second day, the free flap became dusky and revision surgery was planned (Fig. 1). The flap was taken down and was replaced by a large pectoralis major myocutaneous (PMMC) flap to cover the intra-oral defect and part of the facial defect. The PMMC flap did not cover the defect completely and the area in front of left ear was left open (Fig. 2). Patient was managed conservatively and later

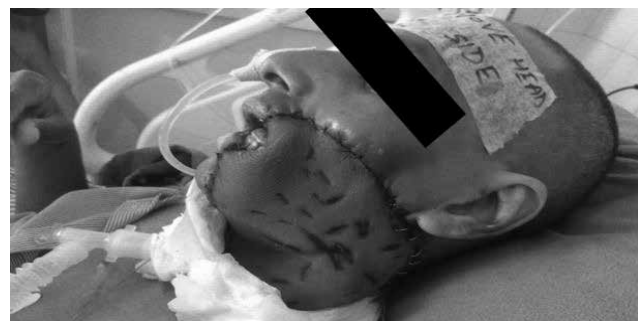


Figure 1. Free flap getting dusky at post-op Day 2.

\*Consultant General Surgeon

†Junior Consultant

‡Consultant Oncosurgeon

#Consultant Medical Oncologist

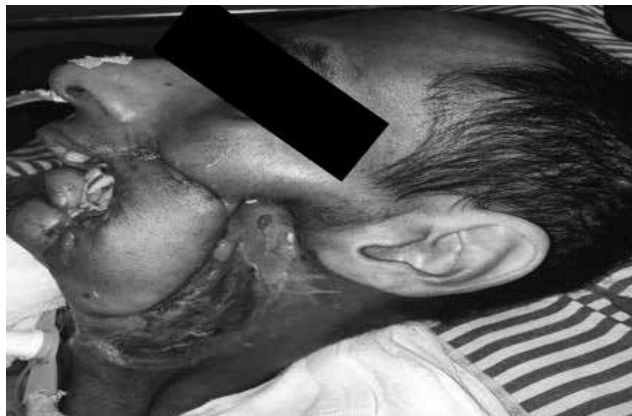Grecian Super Speciality Hospital, Mohali, Punjab

Address for correspondence

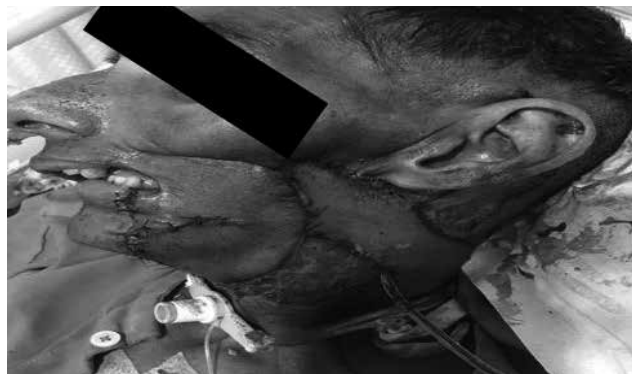
Dr Vijay Jagad

House No. 661, Sector 69, SAS Nagar, Mohali, Punjab · 160 062

E-mail: vijayoncowinmail.com@gmail.com



**Figure 2.** PMMC flap covering part of the defect after taking down the free flap, preauricular area still left uncovered.



**Figure 3.** Complete cover of the defect after using posterior auricular flap.

after complete recovery, posterior auricular flap was used to cover the defect anterior to left ear (Fig. 3).

## DISCUSSION

Post radiotherapy recurrent tumors in head and neck regions are taxing for surgeons to deal with. These cases are met with maximum postoperative complication due to reduced vitality of the tissue. The tissue, after radiotherapy, undergoes fibrosis with severe contractures and reduced blood supply. Reconstruction of the defect after full thickness excision is another challenge. The option of local rotation flap is not viable due to extensive radiotherapy effect and associated contracture. Plastic surgeon needs to bring viable tissue from nonirradiated area to the site of defect and anastomose to it. This can be best done by myofasciocutaneous free flap. Still postoperative complication rate of infection, fistula formation, flap necrosis remains high in these cases.

An ideal free flap which suits best for the defect and has least complication is not derived yet. One has to choose according to the site and size of the defect for optimal functional and cosmetic rectification. This patient of

ours had lesion involving left buccal mucosa right from anterior commissure to the retromolar trigone and also the left lower gingivobuccal sulcus. The left cheek was puckered post radiotherapy, but frank invasion of tumor into the skin was not there. In view of extensive buccal mucosal involvement and thick nonpliable cheek skin, we planned for complete full thickness excision and reconstruction with free flap. Anterolateral thigh flap was used for reconstruction of inner buccal mucosal lining and for the outer skin coverage.

On post op Day 2, flap became dusky and on stroking the flap no prompt bleeding was noted. Plan was made to take down the flap and for local flap cover. Patient's left side face and neck was irradiated and hence there were minimal options for local flap. PMMC flap was used to cover the defect, intra-oral lining was covered completely but the face was partly covered. The area in front of ear was left bare for reconstruction after stabilization of the patient. After 2 weeks, he was taken up for surgery and posterior auricular flap was used. Patient was discharged after complete take up of the flap. Astute knowledge of local flap with preserved blood supply must be there in post radiotherapy cases with failure of free flap.

## CONCLUSION

Free flaps are the best to cover the defect after salvage surgery in head and neck carcinoma. Free flap failure leads to bad functional as well as cosmetic aspect of head neck region. A redo surgery with cover from local flaps is difficult and that compromises the final outcome of the patient.

## SUGGESTED READING

1. Righini CA, Nadour K, Faure C, Rtail R, Morel N, Beneyton V, et al. Salvage surgery after radiotherapy for oropharyngeal cancer. Treatment complications and oncological results. *Eur Ann Otorhinolaryngol Head Neck Dis.* 2012;129(1):11-6.
2. Agra IM, Carvalho AL, Ulbrich FS, de Campos OD, Martins EP, Magrin J, et al. Prognostic factors in salvage surgery for recurrent oral and oropharyngeal cancer. *Head Neck.* 2006;28(2):107-13.
3. Horn D, Bodem J, Freudlsperger C, Zittel S, Weichert W, Hoffmann J, et al. Outcome of heavily pretreated recurrent oral squamous cell carcinoma after salvage resection: A monocentric retrospective analysis. *J Craniomaxillofac Surg.* 2016;44(8):1061-6.
4. León X, Agüero A, López M, García J, Farré N, López-Pousa A, et al. Salvage surgery after local recurrence in patients with head and neck carcinoma treated with chemoradiotherapy or bioradiotherapy. *Auris Nasus Larynx.* 2015;42(2):145-9.