

Enlarged Ovaries Following IVF/ICSI as an Etiology of Obstructive Uropathy Resulting in Acute Renal Failure: A Case Report

PRATIBHA VISHWAKARMA*, PRIYA MOHAN†, KUNDAVI SHANKAR‡, THANGAM R VARMA#

ABSTRACT

In vitro fertilization (IVF) is one of the most comprehensively registered interventions in clinical medicine. IVF is regarded as safe with very few complications. We report a woman who developed acute renal failure due to compression of both ureters from enlarged stimulated ovaries. The condition was diagnosed using magnetic resonance imaging. It was treated with insertion of double-J stents in both ureters and dialysis. Compression of the ureters due to enlarged ovaries should be considered if a patient especially with pre-existing endometriosis develops acute renal failure following IVF.

Keywords: Acute renal failure, *in vitro* fertilization, ovarian hyperstimulation syndrome, ultrasound

During the last 35 years, *in vitro* fertilization (IVF) has become an important treatment option in patients with infertility. Following hormone stimulation, the oocytes are collected from the ovaries transvaginally using ultrasound guidance. The procedure is regarded as safe. The most common complications are hemorrhages, pelvic abscesses and pain. There are also some reports of ureteric damage after puncture by the collecting needle.^{1,2} We report a case, where a woman with pre-existing endometriosis developed acute renal failure due to compression of both ureters from enlarged stimulated ovaries.

CASE REPORT

A 28-year-old woman married for 8 years, with two previous first trimester miscarriages presented to us for treatment of secondary subfertility. She had history of 2 laparoscopies elsewhere suggestive of bilateral tubal block and extensive adhesions between tubes, ovaries

and uterus suggestive of stage IV endometriosis. She had regular cycles with a body mass index (BMI) of 20. She had a past history of surgically corrected atrial septal defect at 5 years of age, asymptomatic; since then with good left ventricular ejection fraction. She had ureteric calculi diagnosed on both sides on ultrasound done outside with no renal changes 3 years back, for which she underwent conservative management.

Her follicle-stimulating hormone (FSH) was 12.3 mIU/L and luteinizing hormone (LH) was 14.2 mIU/L, antimullerian hormone (AMH)-1.2 pmol/L with reduced antral follicle count with 2 cm endometriotic cyst on both ovaries. Kidneys were normal. Husband's semen analysis was normal. Hysteroscopy and trial transfer was done as pre-IVF evaluation. She was counseled for therapeutic trial and a flexible antagonist protocol was followed. Recombinant FSH was used for stimulation. Five oocytes were retrieved under ultrasound guidance after 35 hours of human chorionic gonadotropin (hCG) trigger. Three embryos were fertilized and three 8 cell Grade A embryos were transferred without any difficulty.

Six days following embryo transfer, she reported with loin pain and high-grade fever and reduced urinary output. There was no tenderness on abdominal examination. Investigations revealed normal leukocyte count with more than hundred pus cells on routine urine analysis. Renal function test revealed a picture of pre-renal failure with a serum urea of 100 mg/dL and

*Post Doctor Fellow

†Private Practitioner

‡Senior Consultant

#Medical Director

Institute of Reproductive Medicine and Women's Health
Madras Medical Mission Hospital, Chennai, Tamil Nadu

Address for correspondence

Dr Pratibha Vishwakarma

H. No. 1/2641, Street No. 3, Loni Road, Ram Nagar, Shahdara, New Delhi - 110 032

E-mail: pratibha_vish@yahoo.co.in

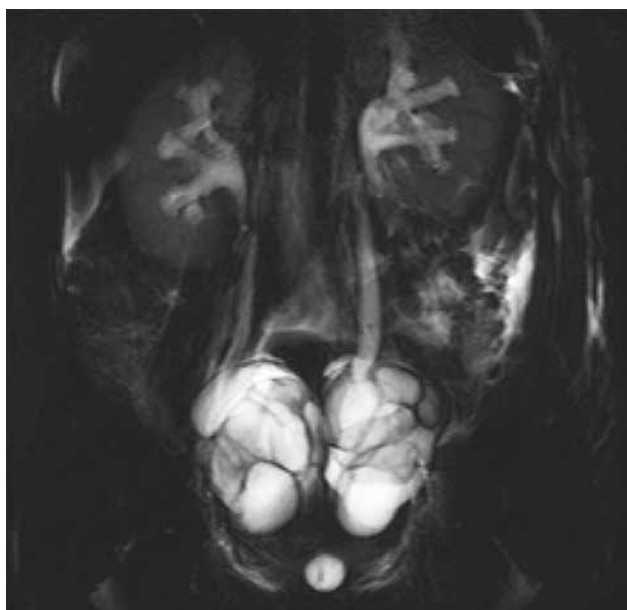


Figure 1. Ultrasound showing bilateral stimulated enlarged ovaries compressing both ureters resulting in bilateral hydronephrosis.

creatinine of 7.9 mg/dL. Serum electrolytes showed hyperkalemia. Investigations to rule out other causes of pyrexia were normal. Ultrasound showed bilateral enlarged ovaries measuring right 5 × 6 cm and left 6 × 7 cm and bilateral hydronephrosis (Fig. 1). Magnetic resonance imaging (MRI) scan showed bilateral hydronephrosis and enlarged ovaries, which led to compression of ureters. She was catheterized and her urine output was only 300 mL/24 hours. Nephrologist's and urologist's opinion were taken. Injection carbapenem following sensitivity to Klebsiella and extended-spectrum beta-lactamase (ESBL) growth on culture was started. Patient was transferred to Nephrology department and dialysis was done as her creatinine showed increasing trend and persistent oliguria. Serum creatinine started to decline following dialysis. Double-J (DJ) stent was inserted. The postoperative course was uneventful and her creatinine level showed declining trends. Oral progesterone was continued as luteal support and on Day 16 of embryo transfer, β -hCG was positive. Her β -hCG showed an increasing trend. Renal sonogram was repeated and it was normal. The patient was asymptomatic and urine culture was negative.

At 6 weeks from last menstrual period (LMP), ultrasound showed evidence of echogenic ring and presence of yolk sac with no cardiac activity and fluid collection was seen in the right adnexa suggestive of right ectopic pregnancy. She was posted for an emergency

laparoscopy as she was hemodynamically stable, which needed conversion to laparotomy in view of frozen pelvis.

Approximately, 1 liter of blood and clots were removed along with necrotic and hemorrhagic tissue scattered in the abdominal cavity. Right tube was the seat of rupture and salpingectomy was done. Right ovary was stuck to the back of uterus, and left ovary stuck to lateral pelvic wall. Abdomen was washed with saline and a drain was placed. Two units of packed cells were transfused postoperatively. Histopathology confirmed ruptured ectopic gestation in the right tube. She was discharged in a stable condition. DJ stent was removed 6 weeks later.

DISCUSSION

Transvaginally, ultrasound-guided oocyte retrieval has become the gold standard for IVF therapy. It is considered as a well-tolerated, cost-effective and safe procedure.^{3,4} A few cases of ureteral damage due to puncture of the ureter by the collecting needle have been described. In one case, the ureter was compressed by a stimulated ovary in a patient with a transplanted pelvic kidney.⁵ The diagnosis of ureteral compression was confirmed by MRI scan, a procedure without ionizing radiation and which should not cause any harm to fertilized embryos.⁶ Severe pelvic adhesions may have worsened the situation by limiting the normal movement of the ovaries. Ovarian hyperstimulation syndrome (OHSS) is a common complication in assisted reproductive technologies. In spite of frequent occurrence of abdominal compartment syndrome and oliguria in OHSS, acute renal failure secondary to obstructive uropathy is uncommon in OHSS.⁷ Acute renal failure due to a hypovolemic state following production of protein-rich ascites in patients with OHSS has been reported,⁸ but in this case, no ascites and only slight hemoconcentration was noted. The most pronounced finding was the huge enlargement of the ovaries and bilateral hydronephrosis.

To date, there have been just two case reports of obstructive uropathy associated with OHSS.⁹ The patient was diagnosed earlier as having stage 4 endometriosis and frozen pelvis. Even though the complication risk related to IVF is low, one should be aware of a possible compression or damage to the ureters with subsequent development of acute renal failure. Injury, either by direct puncture or extrinsic compression, compromised ureteral function, but did not completely halt urination—a testimony to the resilient nature of this structure and an intimation of

more frequent, unrecognized injury. We, therefore, suggest that obstructive uropathy should also be considered as a possible etiology in patients with enlarged ovaries who develop oliguria or acute renal failure.

REFERENCES

1. Coroleu B, Lopez Mourelle F, Hereter L, Veiga A, Calderon G, Martinez F, et al. Ureteral lesion secondary to vaginal ultrasound follicular puncture for oocyte recovery in in-vitro fertilization. Hum Reprod. 1997;12(5):948-50.
2. Miller PB, Price T, Nichols JE Jr, Hill L. Acute ureteral obstruction following transvaginal oocyte retrieval for IVF. Hum Reprod. 2002;17(1):137-8.
3. Lenz S, Lauritsen JG, Kjellow M. Collection of human oocytes for in vitro fertilization by ultrasonically guided follicular puncture. Lancet. 1981;1(8230):1163-4.
4. Tanbo T, Henriksen T, Magnus Ø, Abyholm T. Oocyte retrieval in an IVF program. A comparison of laparoscopic and transvaginal ultrasound-guided follicular puncture. Acta Obstet Gynecol Scand. 1988;67(3):243-6.
5. Khalaf Y, Elkington N, Anderson H, Taylor A, Braude P. Ovarian hyperstimulation syndrome and its effect on renal function in a renal transplant patient undergoing IVF treatment: case report. Hum Reprod. 2000;15(6):1275-7.
6. Vilos AG, Feyles V, Vilos GA, Oraif A, Abdul-Jabbar H, Power N. Ureteric injury during transvaginal ultrasound guided oocyte retrieval. J Obstet Gynaecol Can. 2015;37(1):52-5.
7. Malbrain ML, Cheatham ML, Kirkpatrick A, Sugrue M, Parr M, De Waele J, et al. Results from the International Conference of Experts on Intra-abdominal Hypertension and Abdominal Compartment Syndrome. I. Definitions. Intensive Care Med. 2006;32(11):1722-32.
8. Winkler J, Pinkas H, Tadir Y, Boner G, Ovadia J. Acute decline in renal function as a consequence of ovarian hyperstimulation syndrome. Nephron. 1992;60(1):104-7.
9. Merrilees DA, Kennedy-Smith A, Robinson RG. Obstructive uropathy as the etiology of renal failure in ovarian hyperstimulation syndrome. Fertil Steril. 2008;89(4):992.e1-2.



CHAT WITH DR KK

Lekin "Non-NLEM Drug" Likhee Kyon

इसको उच्च रक्तचाप के लिए azilsartan लिख दो

लेकिन डॉक्टर यह Non-NLEM दवाई है। हमें इसके बारे में मरीज को बताना होगा। याद नहीं डॉ केके ने कहा था कि हमें अधिकतर, NLEM दवाईयाँ लिखनी चाहिये। NLEM दवाईयाँ सस्ती होने के साथ-साथ सुरक्षित तथा अच्छी गुणवत्ता की होती है। NLEM दवाईयाँ भी non-NLEM दवाईयाँ के अनुरूप है।