

# A Rare Case of Disseminated Tuberculosis with Severe Reactive Thrombocytosis

SHRIKRISHNA SAD\*, PRIYASHA TRIPATHI†, GUNJAN KELA‡, DEVENDRA BARUA#, HARSHA KUMAWAT<sup>§</sup>

## ABSTRACT

Tuberculosis (TB) is a major public health problem in India. Hematological parameters are useful indicators of severity in TB infection. Here, we report a case of a 15-year-old female child who came to us with severe anemia and disseminated TB (pulmonary and abdominal) with severe reactive thrombocytosis. Antitubercular drugs and broad-spectrum antibiotics (for superadded infection) were added and steroid therapy was concurrently started in view of wet type of abdominal TB. Anemia was treated with blood transfusion and hematinics and steroid therapy was gradually tapered off and then withdrawn. Treatment was monitored, and within a duration of 2-3 weeks of treatment, platelet counts showed a falling trend. The child improved clinically and symptomatically. So, she was discharged and was on regular follow-up. We are reporting this case as in this child, there are two contributing factors (anemia and TB) for thrombocytosis. We would also like to stress upon the fact that thrombocytosis can be used as a marker in TB patients, which is already known. None of the cases reported till now have such high platelet count.

**Keywords:** Disseminated tuberculosis, severe reactive thrombocytosis, anemia

**T**uberculosis (TB) is a major public health problem in India.<sup>1</sup> Every day, nearly 30,000 people fall ill with TB and 4,500 people lose their lives to this preventable and curable disease.<sup>2</sup> TB is also the major cause of deaths related to antimicrobial resistance and the leading killer of people with human immunodeficiency virus (HIV).

As per the Global TB Report 2017, the estimated incidence of TB in India was approximately 28,00,000, accounting for about a quarter of the world's TB cases.<sup>3</sup> The differential diagnosis of TB should be entertained in patients with some abnormal hematological findings.<sup>4</sup> Moreover, hematological parameters are useful indicators of severity in TB infection.<sup>5</sup>

Reactive thrombocytosis is defined as an increased number of platelets above  $450 \times 10^9/L$  due to a reaction to a stimulus, e.g., an inflammatory condition.<sup>6</sup> Thrombocytosis occurs in many chronic inflammatory diseases, including TB.<sup>1,6-8</sup> The precise stimulus for increased platelet production in reactive thrombocytosis is not clear, but it is associated with increased numbers of small megakaryocytes in the marrow.<sup>6-8</sup> The raised concentrations of serum thrombopoiesis stimulating activity in patients with pulmonary TB suggest the presence of a circulating stimulatory factor, which is in keeping with a previous report of increased thrombopoietin concentrations in patients with TB.<sup>9</sup>

Reactive thrombocytosis is associated with an increase in erythrocyte sedimentation rate (ESR) and acute phase reactants (fibrinogen, VIII.C, von-Willebrand factor [vWF]:Ag, C-reactive protein and interleukin-6 [IL-6]).

Reversible peripheral blood abnormalities are commonly associated with pulmonary TB. Insight into the relationship between hematological abnormalities and mycobacterial infection has come from an understanding of the immunology of mycobacterial infection. The atypical and varied spectrum of clinical presentation of TB poses a diagnostic and therapeutic challenge to the physicians.

\*Junior Resident (2nd Year)

†Junior Resident (1st Year)

‡Associate Professor

#Assistant Professor

§Senior Resident

Dept. of Pediatrics

Sri Aurobindo Institute of Medical Sciences, Indore, Madhya Pradesh

**Address for correspondence**

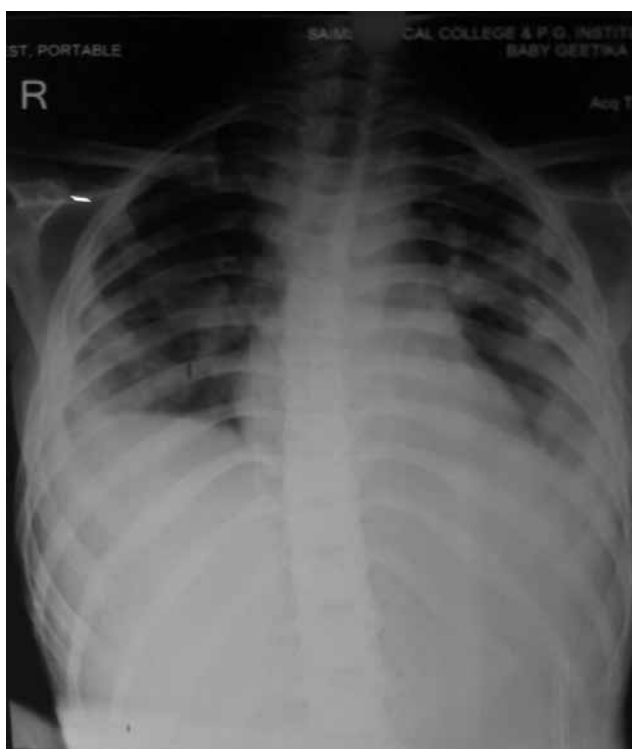Dr Priyasha Tripathi

Junior Resident

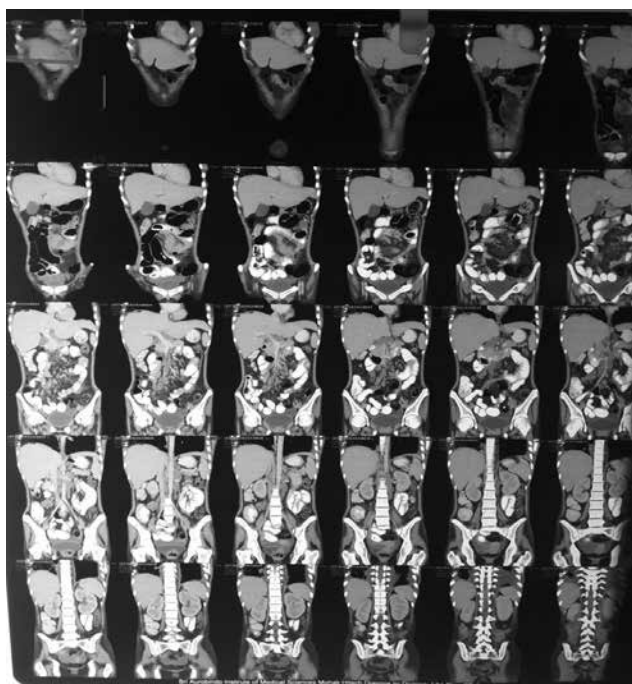
Dept. of Pediatrics

Sri Aurobindo Institute of Medical Sciences, Indore, Madhya Pradesh

E-mail: drpriyasha21@gmail.com



**Figure 1.** Chest X-ray suggestive of B/L ICD *in situ* with B/L pleural effusion (left > right) and B/L consolidation.



**Figure 2.** CECT abdomen - Multiple mild segmental bowel wall thickening in mid and distal ileal loops in infraumbilical region, with mild proximal small bowel dilatation and enlarged necrotic mesenteric/para-aortic lymph nodes. Mid wall thickening is also seen at the ileocecal junction. Mild ascites and bilateral pleural effusion. CECT suggestive of Koch's abdomen.

## CASE REPORT

A 15-year-old girl presented to us with complaints of low-grade intermittent fever, more during night, since 1½ month with mild productive cough, with history of significant weight loss, weakness and poor appetite.

On admission, the patient presented with severe pallor, tachypnea, tachycardia and significant cervical lymphadenopathy. On systemic examination, pleural effusion and ascites were found which were confirmed by investigations (Figs. 1-3). On further work-up, the patient was provisionally diagnosed with disseminated TB (pulmonary and abdominal) with severe anemia and severe reactive thrombocytosis.

Anemia was treated and antitubercular therapy was started along with antibiotics for superadded infection. With appropriate treatment, the patient improved clinically and platelet counts came within normal limits (Figs. 4 and 5). The patient was discharged on regular follow-up.



**Figure 3.** 64 Slice MDCT chest - Multiple patchy dense areas of consolidation with adjacent centrilobular nodule seen, scattered in both lung segments with upper lobe predominance. Moderate bilateral pleural effusion and subsegmental collapse seen. IC drain is seen *in situ*. Multiple discrete lymph nodes are seen in pre- and paratracheal/subcarinal, bilateral hilar region, upper abdomen para-aortic region, average size 1-2.5 cm.

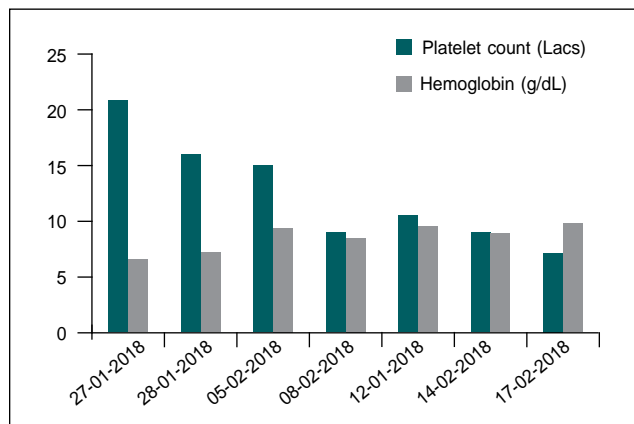


Figure 4. The course of platelet count and hemoglobin during treatment course for TB.

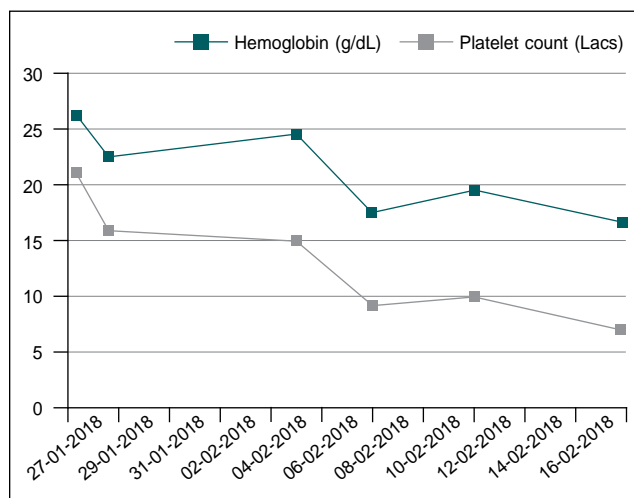


Figure 5. The course of platelet count and hemoglobin during treatment course for TB.

## DISCUSSION

TB is a major health problem in India. The association between TB and deranged hematological profile (severe anemia and severe thrombocytosis), an uncommon occurrence, has been reported in our study, which is similar to a study done in the year 1987 at the Dept. of Medicine, University of Witwatersrand, Johannesburg, South Africa in 122 patients that suggested a direct correlation between platelet counts and chronic inflammatory disease, like TB.<sup>10</sup>

In other studies, Olaniyi et al<sup>11</sup> and Akintunde et al<sup>12</sup> studied the hematological profile of patients with pulmonary TB in Ibadan, Nigeria and reported that thrombocytosis occurred in 12.9% and 18% of patients, respectively. On the other hand, in the study done in Dept. of Hematology, Port Sudan Ahlia College, Port Sudan, Sudan, assessment of reactive thrombocytosis and

ESR in patients with pulmonary TB was done in 100 randomly selected patients. Thrombocytosis was reported in 20% of the patients. Therefore, presence of such hematological changes should raise the suspicion of pulmonary TB.<sup>13</sup>

Reactive thrombocytosis is found in a number of infectious diseases like TB. In another study done in the year 2017 in the Dept. of Medicine, Rajiv Gandhi Medical College, Thane, India, 112 TB patients were randomly selected. Out of these, thrombocytosis was detected in 84 (75%) of the TB patients.<sup>14</sup> The objective of this study was to prove that thrombocytosis can be used as a marker for TB.

The precise stimulus for increased platelet count is not clear but due to inflammatory process, there is increase in megakaryocytes in the bone marrow. In another study done at Baptist Hospital, Miami, 37 patients with positive TB culture were selected out of which, 19 patients had thrombocytosis.<sup>15</sup>

On the contrary, in our case, there were two stimulatory factors for thrombocytosis - severe anemia and chronic inflammatory disease like TB.

## REFERENCES

- Bannerman RG. Blood-plate count in pulmonary tuberculosis. *Lancet*. 1924;204(5273):593-5.
- World Health Organization. Tuberculosis (TB). Available at: [http://www.who.int/tb/features\\_archive/world\\_TB\\_day\\_2018\\_campaign/e/](http://www.who.int/tb/features_archive/world_TB_day_2018_campaign/e/).
- Indian TB Report 2018: Revised National TB Control Programme - Annual Status Report. Available at: <https://tbcindia.gov.in/showfile.php?lid=3314>.
- Marchasin S, Wallerstein RO, Aggeler PM. Variations of the platelet count in disease. *Calif Med*. 1964; 101:95-100.
- Wintrobe MM, Lee GR, Boggs DR, Bithell TC, Athens JW, Forster J. *Clinical Hematology*. 7th Edition, Philadelphia: Lea Febiger; 1974. pp. 1103-18.
- Williams WJ. Thrombocytosis. In: Williams WJ, Beutler E, Erslev A, Lichtman MA, (Eds.). *Hematology*. 3rd Edition, New York: McGraw-Hill Book Company, 1983. pp. 1342-5.
- Harker LA, Finch CA. Thrombokinetics in man. *J Clin Invest*. 1969;48(6):963-74.
- Tranum BL, Haut A. Thrombocytosis: platelet kinetics in neoplasia. *J Lab Clin Med*. 1974;84(5):615-9.
- Shreiner DP, Weinberg J, Enoch D. Plasma thrombopoietic activity in humans with normal and abnormal platelet counts. *Blood*. 1980;56(2):183-8.
- Baynes RD, Bothwell TH, Flax H, McDonald TP, Atkinson P, Chetty N, et al. Reactive thrombocytosis in pulmonary tuberculosis. *J Clin Pathol*. 1987;40(6):676-9.

11. Olaniyi JA, Aken'Ova YA. Haematological profile of patients with pulmonary tuberculosis in Ibadan, Nigeria. *Afr J Med Med Sci.* 2003;32(3):239-42.
12. Akintunde EO, Shokunbi WA, Adekunle CO. Leucocyte count, platelet count and erythrocyte sedimentation rate in pulmonary tuberculosis. *Afr J Med Med Sci.* 1995;24(2):131-4.
13. Bashir AB, Ageep Ali K, Abufatima AS, Mohamedani AA. Reactive thrombocytosis and erythrocyte sedimentation rate in patients with pulmonary tuberculosis. *J Med Lab Diagn.* 2014;5(3):29-34.
14. Rathod S, Samel DR, Kshirsagar P, Pokar M. Thrombocytosis: can it be used as a marker for tuberculosis? *Int J Res Med Sci.* 2017;5(7):3082-6.
15. Renshaw AA, Gould EW. Thrombocytosis is associated with *Mycobacterium tuberculosis* infection and positive acid-fast stains in granulomas. *Am J Clin Pathol.* 2013; 139(5):584-6.



# Make sure

## DURING MEDICAL PRACTICE

**SITUATION:** A 40-year-old man constantly had systolic BP >140 mmHg and diastolic BP >90 mmHg.



© IJCP GROUP

**LESSON:** The Eighth Joint National Committee (JNC8) guidelines for the management of high BP in adults recommend initiation of pharmacologic therapy to lower BP at systolic BP  $\geq$  140 mmHg and at diastolic BP  $\geq$  90 mmHg.

*JAMA.* 2014;311(5):507-20.