

Photo Quiz

ACQUIRED NAIL DISORDER IN AN OLDER PERSON

A 78-year-old man who had not seen a physician in many years had pain in his feet, but no history of trauma. He wore sneakers and was able to walk well without a cane or walker. He had not cut his toenails for an extended period and had poor hygiene. He was independent in activities of daily living. He had no relevant medical history and was not taking medications.

On physical examination, his lower extremities were cool with thin, dry, and scaly skin. Bilateral thick, elongated, and curved toenails 5 to 8 cm long were digging into the skin (Figure 1). Keratin debris was noted over the toes and interdigital spaces, and there was trace pitting edema on both legs. Dorsalis pedis pulses were diminished bilaterally. Sensation was grossly decreased to light touch.

Question

Based on the patient's history and physical examination findings, which one of the following is the most likely diagnosis?

- A. Onychauxis.
- B. Onychogryphosis.
- C. Onychorrhexis.
- D. Onychoschizia.
- E. Trachyonychia.

Discussion

The answer is B: onychogryphosis. The condition is characterized by thickened, discolored, severely elongated, curved nails with claw-like deformity (ram's horn nail). Onychogryphosis occurs mostly in older or homeless persons as a result of chronic neglect, trauma, or poor nail care.¹⁻⁴ Although it occurs most commonly in the great toenails, any nail can be affected. Underlying peripheral vascular disease, poor circulation, and associated onychomycosis may occur, as in this patient.¹⁻⁴

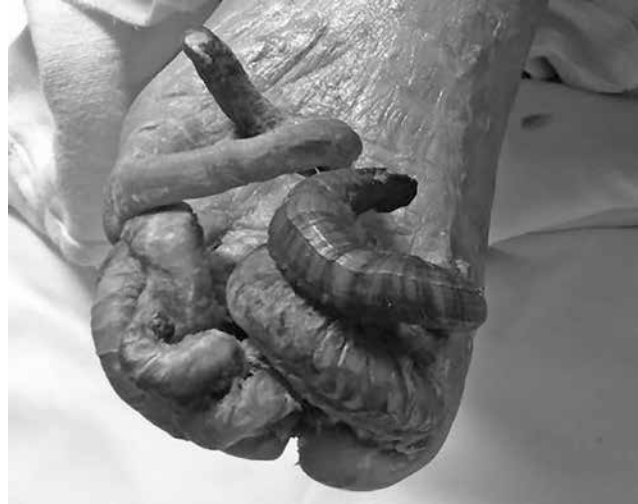

Figure 1.

Treatment of patients with onychogryphosis includes trimming the nails with an electric burr and filing subungual hyperkeratosis. Rough edges of the toenail should be smoothed down. Other treatments include avulsion of the nail plate and surgical or chemical destruction of the nail matrix with phenol or a carbon-dioxide laser.⁵⁻⁷ The choice of treatment should take into account peripheral vascular circulation, treatment compliance, and potential complications. Periodic repeated treatments are usually required for maintenance.⁵ Any coexisting fungal infection should be treated appropriately.^{1,2}

Onychauxis is a thickening of the nail plate with discoloration that occurs in older persons. It may be associated with subungual hyperkeratosis of the nail bed. Presenting symptoms may include pain and onycholysis, and underlying fungal infection, hemorrhage, or ulceration of the nail bed.³⁻⁵

Onychorrhexis is increased nail brittleness with longitudinal ridging and fissuring of the nail plate. It can occur with several conditions, such as hypothyroidism, anemia, or bulimia. It may also be associated with use of nail polish remover or nail picking.^{3,4}

Onychoschizia is splitting of the distal lamella of the nail horizontally at the free edge. It is often due to frequent water or detergent exposure.⁴

Trachyonychia, also known as twenty-nail dystrophy, is an idiopathic condition characterized by longitudinal

Source: Adapted from Am Fam Physician. 2017;95(8):519-520.

Summary Table

Condition	Limb abnormalities
Onychauxis	Thickening of the nail plate with discoloration in older persons; may be associated with subungual hyperkeratosis of the nail bed
Onychogryphosis	Thickened, discolored, severely elongated nails; curled, claw-like deformity (ram's horn); underlying peripheral vascular disease, poor circulation, or associated onychomycosis may occur
Onychorrhexis	Increased nail brittleness with longitudinal ridging and fissuring of the nail plate
Onychoschizia	Splitting of the distal lamella of the nail horizontally at the free edge; often due to water or detergent exposure
Trachyonychia	Thinned nail with longitudinal ridges, pitting, and roughening of the proximal nail surface

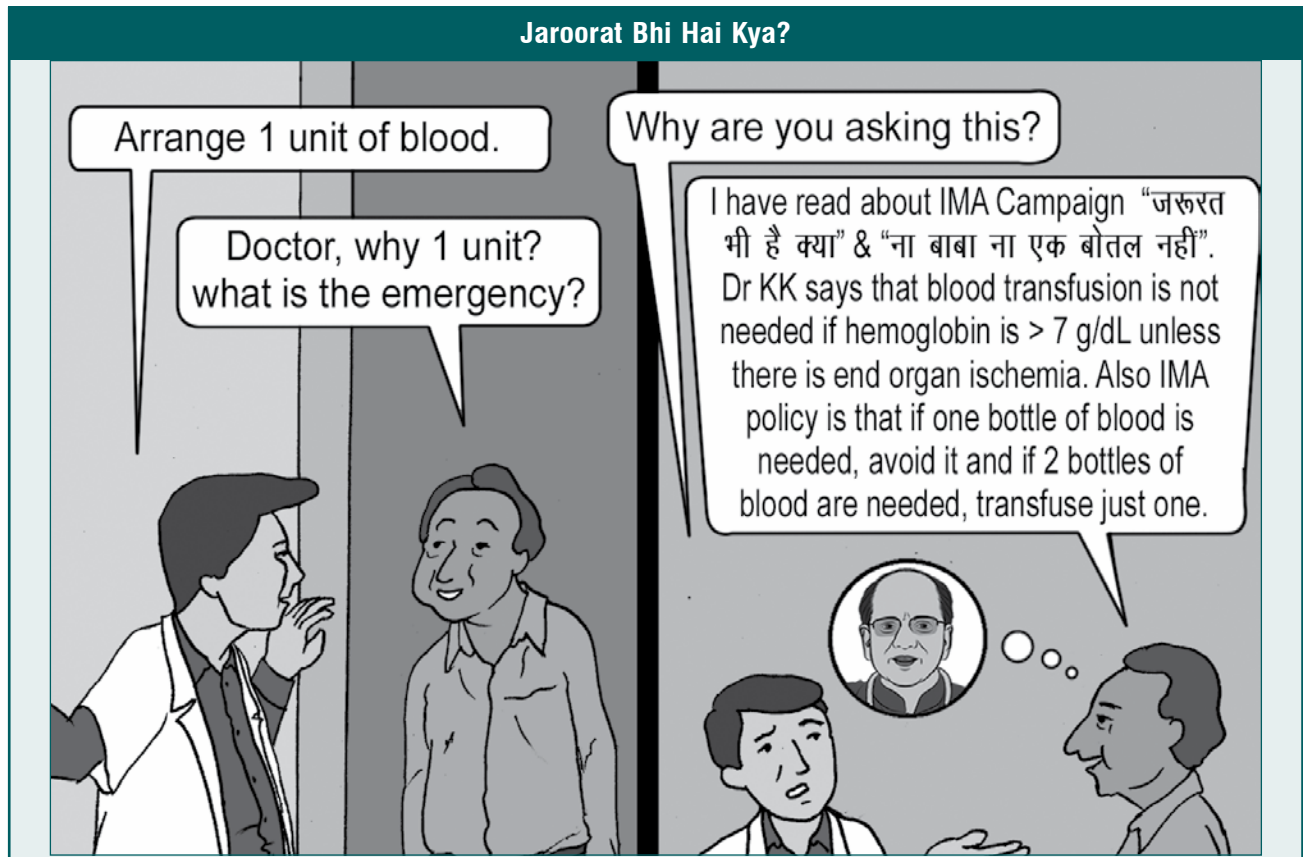
ridges, pitting, and roughening of the nail surface. This condition may also occur with inflammatory diseases, such as lichen planus, psoriasis, or alopecia areata.^{3,4}

REFERENCES

- Mumoli N. Ram's horn nails. *Med J Aust.* 2011;195(4):202.
- Goldsmith LA, Fitzpatrick TB, eds. *Fitzpatrick's Dermatology in General Medicine.* 8th ed. New York, NY: McGraw-Hill Medical; 2012.
- Usatine R, ed. *The Color Atlas of Family Medicine.* New York, NY: McGraw-Hill; 2009.
- Singh G, Haneef NS, Uday A. Nail changes and disorders among the elderly. *Indian J Dermatol Venereol Leprol.* 2005;71(6):386-392.
- Fowler AW. Excision of the germinal matrix: a unified treatment for embedded toe-nail and onychogryphosis. *Br J Surg.* 1958;45(192):382-387.
- Kaplan I, Labandter H. Onychogryphosis treated with the CO2 surgical laser. *Br J Surg.* 1976;29(1):102-103.
- Andrew T, Wallace WA. Nail bed ablation—excise or cauterise? A controlled study. *Br Med J.* 1979; 1(6177):1539.



CHAT WITH DR KK



In Anemia



Strike the Balance with the Right Hematinic

Rx DEXORANGE®

Syrup/Capsules/Paediatric Syrup
(Ferric Ammonium Citrate)

The Masterpiece in Hematinics

Rx in Anemia associated with

- Pregnancy & Lactation
- General Weakness
- Menorrhagia
- Chemotherapy induced Anemia
- Nutritional & Iron deficiency
- Lack of Appetite
- Chronic Gastrointestinal Blood Loss
- Chronic Kidney Disease

