

Photo Quiz

HYPERKERATOTIC PLAQUES ON HANDS

A 10-year-old boy presented with a rash on both hands that had been present for at least several weeks. He had not worn any new gloves or other clothing. He had received a new video game at Christmas about five months prior and had played it for at least three to four hours every day since.

On physical examination, he was not in distress. There were hyperkeratotic plaques on the lateral aspect of both of his index fingers (Figure 1). The lesions were symmetric, lichenified with erosions, and painful. The rest of the dermatologic examination was unremarkable.

Question

Based on the patient's history and physical examination findings, which one of the following is the most likely diagnosis?

- A. Frictional hyperkeratotic hand dermatitis.
- B. Irritant contact dermatitis.
- C. Palmoplantar keratoderma.
- D. Psoriasis.
- E. Tinea manuum.

Discussion

The answer is A: frictional hyperkeratotic hand dermatitis. The patient's lesions developed at the sites of direct contact with his video game controller, and the diagnosis was made based on the repetitive friction and trauma caused by overuse of the video game. He was successfully treated by significantly reducing his video game use and applying topical emollients.

With the increased use of computers and electronic devices by persons of all ages over the past 20 years, new manifestations related to repetitive mechanical activities may occur, affecting superficial structures, such as the skin, and less commonly deeper structures, such as nerves and tendons. Frictional hyperkeratotic hand dermatitis develops as a result

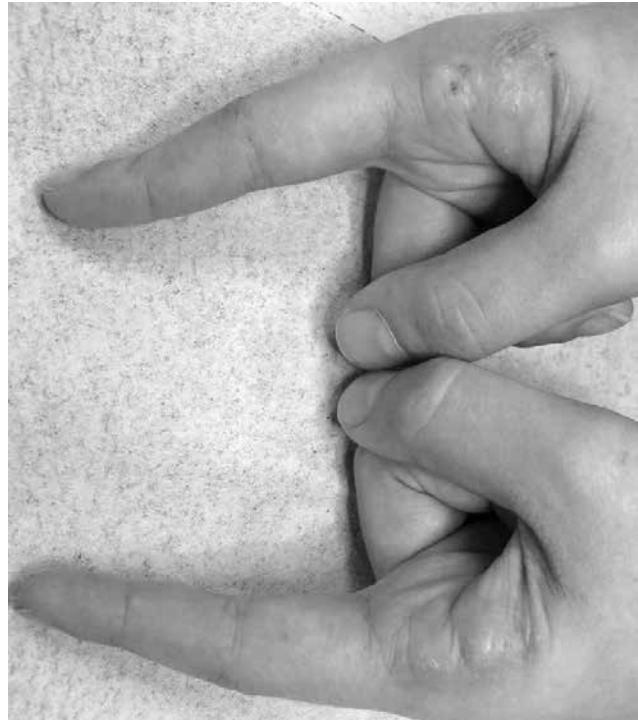


Figure 1.

of repetitive mechanical friction, trauma, vibration, or pressure. Several terms have been used to describe injuries from overuse of electronic devices, including "Nintendonitis," "Wiitis," and "Playstation thumb."

Irritant contact dermatitis is a localized inflammatory response to physical, environmental, or chemical agents. It usually presents as erythema, erosions, and scaling and may cause pruritus or a burning sensation. Mild symptoms result from prolonged or repeated exposure to the irritants. Strong chemicals may produce a direct reaction similar to that of a thermal burn.¹

Palmoplantar keratodermas are a heterogeneous group of disorders with hyperkeratotic thickening of the palms and soles.² These disorders may be hereditary or acquired. The diffuse form has a thick, symmetric hyperkeratosis involving the entire palm and sole. The focal form has hyperkeratotic lesions at sites of recurrent friction, mainly on the feet. The punctate form is characterized by punctate keratotic papules on the palms and soles.³

Psoriasis is a chronic, immune-mediated inflammatory disease.⁴ It presents as erythema, thickening, and

Source: Adapted from Am Fam Physician. 2016;93(11):945-946.

Summary Table

Condition	Characteristics	Etiology
Frictional hyperkeratotic hand dermatitis	Hyperkeratotic plaques of the hands that are symmetric, lichenified with erosions, and painful	Repetitive mechanical friction, trauma, vibration, or pressure
Irritant contact dermatitis	Erythema, erosions, and scaling; possibly pruritus or a burning sensation	Localized inflammatory response to physical, environmental, or chemical agents
Palmoplantar keratodermas	Diffuse form: thick, symmetric hyperkeratosis involving the entire palm and sole Focal form: hyperkeratotic lesions at sites of recurrent friction, mainly on the feet Punctate form: punctate keratotic papules on the palms and soles	Hereditary (autosomal recessive, autosomal dominant, or X-linked), or acquired
Psoriasis	Erythema, thickening, and scaling of skin; deep, painful fissures or palmoplantar pustulosis	Immune-mediated inflammatory disease
Tinea manuum	Diffuse, dry, scaling hyperkeratotic lesions; possibly vesicular, exfoliating, erythematous, annular lesions on the dorsal surface of the hand	Superficial, noninflammatory dermatophyte infection

scaling of the skin. It may be accompanied by deep, painful fissures or palmoplantar pustulosis.

Tinea manuum is a superficial, noninflammatory dermatophyte infection of the hand. It usually presents as diffuse, dry, scaling hyperkeratotic lesions, although vesicular, exfoliating, erythematous, annular lesions on the dorsal surface of the hand have also been reported. Unilateral tinea manuum is associated with moccasin-type tinea pedis or onychomycosis, a pattern sometimes referred to as two feet, one hand disease.⁵

REFERENCES

1. Usatine RP, Riojas M. Diagnosis and management of contact dermatitis. *Am Fam Physician*. 2010;82(3):249-255.
2. Schiller S, Seebode C, Hennies HC, Giehl K, Emmert S. Palmoplantar keratoderma (PPK): acquired and genetic causes of a not so rare disease. *J Dtsch Dermatol Ges*. 2014;12(9):781-788.
3. Zamiri M, van Steensel M, Munro C. Inherited palmoplantar keratodermas. In: Fitzpatrick TB, Goldsmith LA, eds. *Fitzpatrick's Dermatology in General Medicine*. 8th ed. New York, NY: McGraw-Hill Medical; 2012: 538-550.
4. Rallis E, Kintzoglou S, Verros C. Ustekinumab for rapid treatment of nail psoriasis. *Arch Dermatol*. 2010;146(11):1315-1316.
5. Schieke SM, Garg A. Superficial fungal infection. In: Fitzpatrick TB, Goldsmith LA, eds. *Fitzpatrick's Dermatology in General Medicine*. 8th ed. New York, NY: McGraw-Hill Medical; 2012:2277-2327.



What is One Peg of Alcohol?

Definitions of a "standard drink" differ, both within and between countries.

- United States: 14-15 g alcohol (0.5 to 0.6 fl oz), equivalent to 12 oz beer, 5 oz wine and 1.5 oz of 80 proof liquor
- Great Britain: 8 g alcohol
- Japan: 19.75 g alcohol
- India: 10 g alcohol
- Patiala peg: 20 g alcohol
- National Institute on Alcohol Abuse and Alcoholism (NIAAA): 12 g of alcohol (equivalent to 360 mL (12 oz) of beer, 150 mL (5 oz) of wine, or 45 mL (1.5 oz) of 80 proof distilled spirits)
- Most countries: 8-12 g alcohol.