

# Pseudo-Ventricular Tachycardia in Parkinson's Disease

MONIKA MAHESHWARI\*, SONAM†

## ABSTRACT

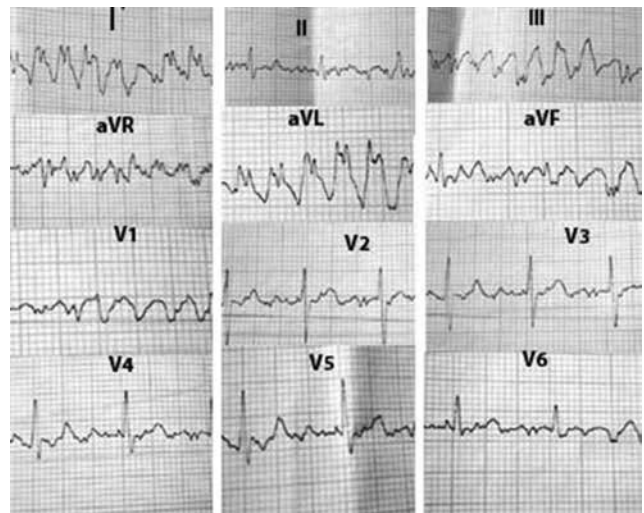
We report herein a patient with Parkinson's disease whose electrocardiogram mimicked ventricular tachycardia due to Parkinson's tremors.

**Keywords:** Parkinson's disease, ventricular tachycardia

**A**rtefact in electrocardiogram (ECG) caused by Parkinson's tremor can mimic wide complex ventricular tachycardia (VT) and give rise to unwarranted further investigations and clinical intervention.<sup>1</sup> Hence, the need of the hour is to increase awareness and training to avoid misdiagnosing these artifacts as potentially life-threatening cardiac arrhythmias. We report herein one such case of an elderly male with Parkinson's tremors.

## CASE REPORT

A 76-year-old man was referred to the outdoor department for routine preoperative cardiac evaluation before undergoing prostatic surgery. His pulse was 100/min, and blood pressure 120/70 mmHg. His cardiovascular examination was unremarkable with normal heart sounds and no audible murmur. His central nervous system examination revealed resting tremors in fingers of upper limbs. He also had characteristic mask-like facies. On laboratory investigations, blood biochemistry was normal including serum electrolytes and thyroid function test. His 12-lead ECG revealed run of broad QRS complexes in multiple leads (Fig. 1). However, clinically hemodynamic stability of the patient raised suspicion of pseudo-VT. Further diagnostic clues for the ECG artifacts were presence of (1) intervening spike of 'R' waves of normal QRS, in midst of run of broad QRS complexes in Lead III, aVR, aVF and V1



**Figure 1.** ECG showing broad QRS complexes in multiple leads.

and (2) normal width QRS with regular R-R interval in chest leads V2-V6 and Lead II. So, our patient did not undergo any cardiac intervention for this artifact simulating VT and was continued on anti-Parkinson's medication as per Neurologist's advice.

## DISCUSSION

The tremor of Parkinson's disease has been known to induce ECG artifacts resembling cardiac arrhythmias, simulating both atrial and ventricular tachyarrhythmias.<sup>1,2</sup> Knight et al<sup>3</sup> published an interesting case-series review on the clinical consequences of misdiagnosing ECG artifact as VT in 12 patients, of whom, 9 were asymptomatic at the time of the ECG recording. Llinas et al<sup>4</sup> reported a case of an elderly patient with Parkinson's who presented with a history of collapses. VT on her ECG was thought to be the cause but her falls were related to the postural

\*Professor

†Resident - 3rd Year

JLN Medical College, Ajmer, Rajasthan

**Address for correspondence**

Dr Monika Maheshwari

Naveen Niwas, 434/10, Bapu Nagar, Ajmer, Rajasthan

E-mail: opm11@rediffmail.com

instability associated with Parkinson's disease. Interestingly, patients with Parkinson's disease may also suffer from cardiovascular autonomic dysfunction,<sup>5</sup> which can cause QT prolongation and lead to ventricular arrhythmias and sudden death. Therefore, identifying ECG artifact masquerading as VT requires careful review of the temporal relation of body movement to the ECG recording, close scrutiny of the ECG tracing, especially looking for normal QRS complexes within the artifact, eliciting physical signs of atrioventricular dissociation such as variability of the jugular venous pulse amplitude or loudness of the first heart sound, as well as the use of transesophageal ECG recording for complex cases. This case also highlights the importance of assessing a 12-lead ECG instead of depending on single channel telemonitor to make the diagnosis. If this patient was on a single channel telemonitor/Holter monitor, misdiagnosis of VT would have been made, depending on the channel used. Tremor artifact is most prominent in limb leads and represents the action potentials of striated muscle.<sup>6</sup>

This case report emphasizes that treating doctor should remain vigilant and avoid unnecessary diagnostic and therapeutic interventions such as initiation of long-term

antiarrhythmic and anticoagulant drugs, diagnostic cardiac catheterization and even implantation of permanent pacemakers or cardiac defibrillators in such pseudo-cardiac arrhythmias.

#### REFERENCES

1. Bhatia L, Turner DR. Parkinson's tremor mimicking ventricular tachycardia. *Age Ageing*. 2005;34(4):410-1.
2. Prabhavathi B, Ravindranath KS, Moorthy N, Manjunath CN. Pseudo-atrial flutter/fibrillation in Parkinson's disease. *Indian Heart J*. 2009;61(3):296-7.
3. Knight BP, Pelosi F, Michaud GF, Strickberger SA, Morady F. Clinical consequences of electrocardiographic artifact mimicking ventricular tachycardia. *N Engl J Med*. 1999;341(17):1270-4.
4. Llinas R, Henderson GV. Images in clinical medicine. Tremor as a cause of pseudo-ventricular tachycardia. *N Engl J Med*. 1999;341(17):1275.
5. Oka H, Mochio S, Sato H, Katayama K. Prolongation of QTc interval in patients with Parkinson's disease. *Eur Neurol*. 1997;37(3):186-9.
6. Robottom BJ, Weiner WJ. Teaching neuroImages: Rest tremor mimicking ventricular tachycardia. *Neurology*. 2010;75(23):2134.



#### CHAT WITH DR KK

