

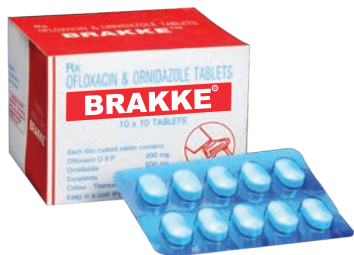

No more Diarrhoeal Discomfort

Rx

BRAKKE[®] Tab

(Ofloxacin 200 mg + Ornidazole 500 mg)



Rx

Lactiviest[™] Sachets

(*Saccharomyces boulardii*: Not less than 500 million live yeast cells)



Inadvertently Lost Cannula Sheath in External Jugular Vein: A Rare Incident

SANJIV K GOYAL*, SANDEEP SINGH MAAVI†, ASHISH GARG‡, VIJAY JAGAD#

ABSTRACT

External jugular vein cannulation is frequently used method for IV access and medications in cases where there is difficulty securing IV access in extremity. It is generally a safe procedure with fairly good technical success rate. Here we discuss a case of lost cannula sheath with in the external jugular vein that was recovered successfully surgically.

Keywords: External jugular vein, cannulation, lost cannula sheath

CASE REPORT

External jugular vein (EJV) has been used for IV access in many different condition right from trauma, burns involving extremities and in conditions like sepsis. It has been proved to be valuable for providing fluid and medications to the patients in whom cannulation of extremities is found difficult. We have a case in which the patient presented to our emergency department with chief complaints of pain in abdomen and vomiting for past 3 days.

On presentation, patient was dehydrated and was in shock. Multiple attempts were made for securing IV access over the extremities but were all futile. Plan was to insert a wide bore cannula in right EJV for fluid resuscitation and for giving medication. Patient was shifted to intensive treatment unit (ITU).

On further blood investigation and CT scan, it was revealed that patient was suffering from acute necrotizing pancreatitis. Patient was managed with fluid resuscitation, nil per mouth and IV antibiotics. On third day of admission, on examination of the neck, it was revealed that the cannula inserted in right EJV

had fractured at the junction with the port site and complete sheath of the cannula had got lost in EJV.

Ultrasound on the local area was done and that revealed a well-defined linear artefact with parallel echogenic lines, of approximate size 3.9 cm, in distal part of right EJV with thrombus in the surrounding region, upper part of the right EJV was normal. This was suggestive of broken catheter with thrombus in EJV.

After discussion, it was decided to explore under general anesthesia. Patient was taken to the operation theater and after giving general anesthesia, part was painted and draped, transverse neck skin incision was given, flaps raised and the right EJV located (Fig. 1).

Phlebotomy done and cannula sheath removed safely (Fig. 2). Complete hemostasis was achieved and skin was closed with staplers. Patient was then inserted central venous line in left subclavian vein. She was managed in ITU for another 4 days and after complete resolution of pancreatitis, she was shifted to general ward and discharged from there after 2 days.

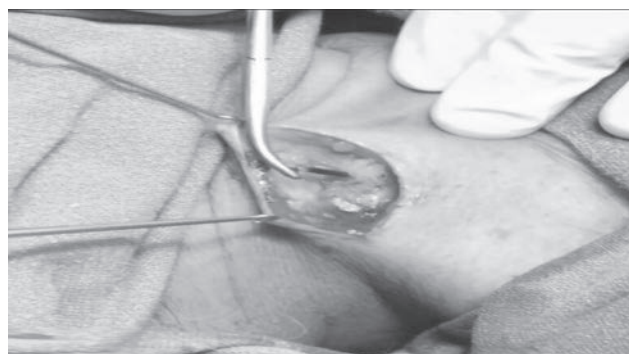

Figure 1. Cannula sheath within the right EJV seen at exploration.

*Consultant General Surgeon

†Senior Resident in General Surgery

‡Consultant Critical Care Medicine

#Consultant Surgical Oncologist

Grecian Super Speciality Hospital, Mohali, Punjab

Address for correspondence

Dr Sanjiv K Goyal

Flat No. 004, Tower No. 22, Royale Estate, Chandigarh Ambala Highway, Zirakpur - 140 603, Punjab

E-mail: sanjivgoyal92@yahoo.in

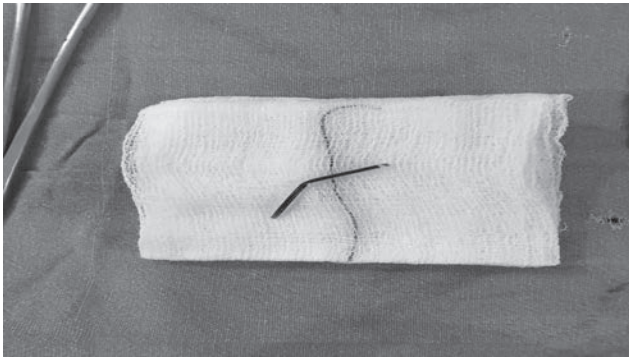


Figure 2. Extracted cannula sheath.

DISCUSSION

EJV has long been used as access for fluid resuscitation and drug administration in indoor patients.¹ Cannulation of EJV is generally done under conditions where peripheral IV access to the extremities is difficult such as in cases of shock, extremity trauma or burns involving extremity.² Cannulation of EJV is pretty easy and especially right side is used, usually 16 or 18 gauge canula is inserted for access. The technical success rate has ranged from 70% to 90%.³ There are certain contraindications of EJV cannulation such as agitated and uncooperative patient, patient with short neck or with neck mass, patient having continuous vomiting.

EJV cannulation is not a fully safe procedure, there have been multiple complication associated with it.

Hematoma, infection, air embolism and subcutaneous infiltration of drug are among the top in the list. Here we report a patient who had undergone EJV cannulation for IV access and had cannula fractured with the complete sheath within the right EJV. With ultrasound guidance, the sheath was confirmed within the right EJV. Under general anesthesia, local exploration was done and the sheath was recovered. Patient tolerated the procedure well and after resolving her pancreatitis issue, she was discharged home.

CONCLUSION

EJV has been tried and tested method for IV access. It is tolerated well in most of the patients with few complications to be kept in mind. Daily vigilance and proper technique helps to reduce the complications rate associated with it.

REFERENCES

1. Scales K. Intravenous therapy: a guide to good practice. Br J Nurs. 2008;17(19):S4-S12.
2. Uvelin A, Kolak R, Putnik D. External jugular cannulation is irreplaceable in many situations. Resuscitation. 2010;81(6):773; author reply 774.
3. Chakravarthy M, Krishnamoorthy J, Nallam S, Kolar N, Faris A, Reddy K, et al. External jugular venous route for central venous access: our experience in 563 surgical patients. J Anesth Clin Res. 2011;2:144.



CHAT WITH DR KK

